

A close-up photograph of a person's hands holding a smartphone against the back of a horse. The person is wearing a dark, textured sleeve. The horse's coat is greyish-brown. The smartphone screen displays a dark interface with a green and blue light pattern, suggesting an imaging application. The background is blurred, showing the horse's head and a red halter.

Imaging the equine posterior segment

With the smartphone

Imaging the posterior segment

Approach – “tell a story of the image’s journey”

Understand pros and cons of direct vs indirect ophthalmoscopy

Techniques To master:

- Continuous light- know how to use and how to alter intensity
- Getting close
- Use the LED location on the phone to help you

How to image the:

- Optic nerve head
- Tapetal fundus
- NTF



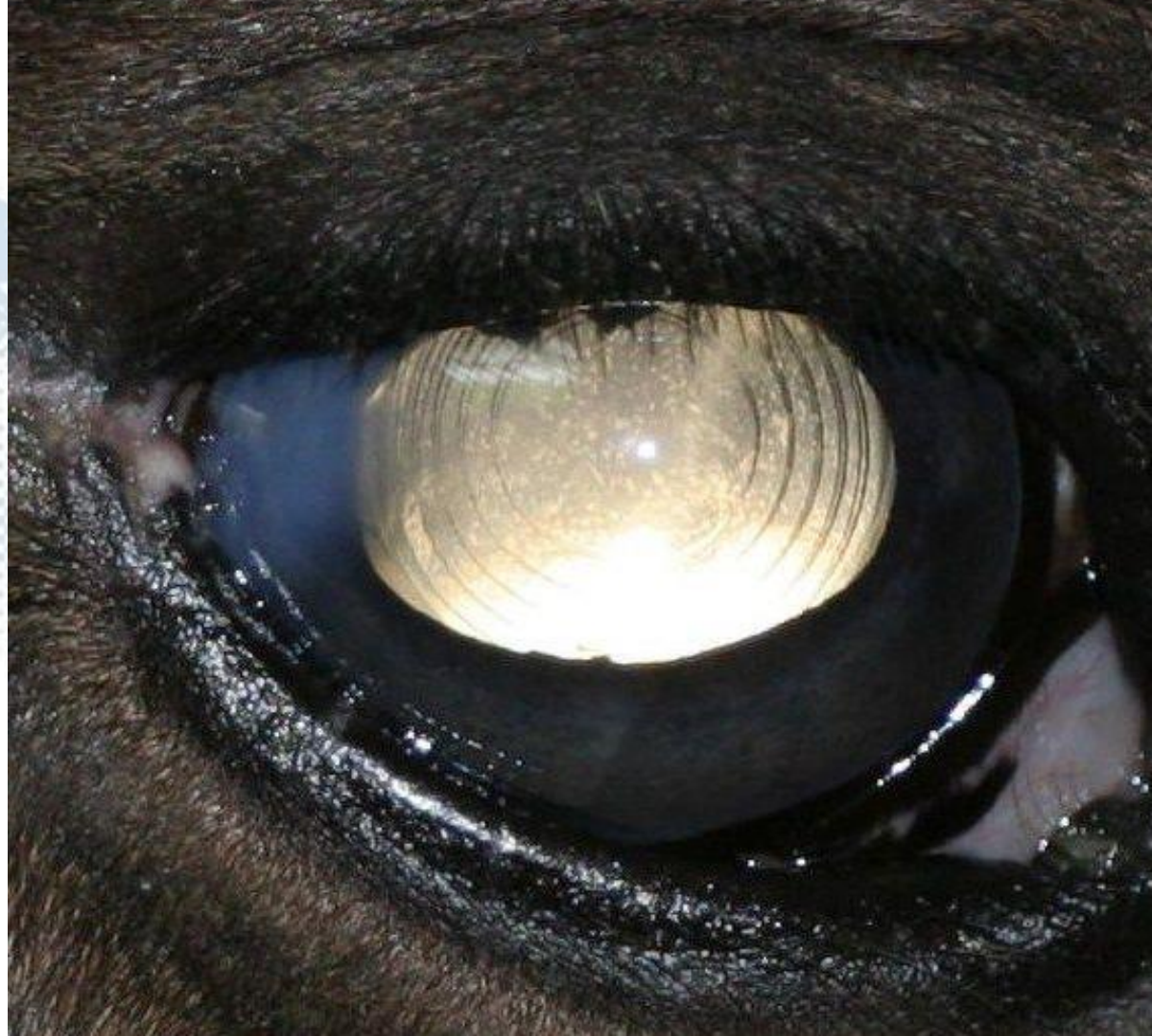The visual axis

Visual axis

Document using distant direct.

Remember to document all 5 angles:

- Nasal
- Temporal
- Superior
- Inferior
- Axial



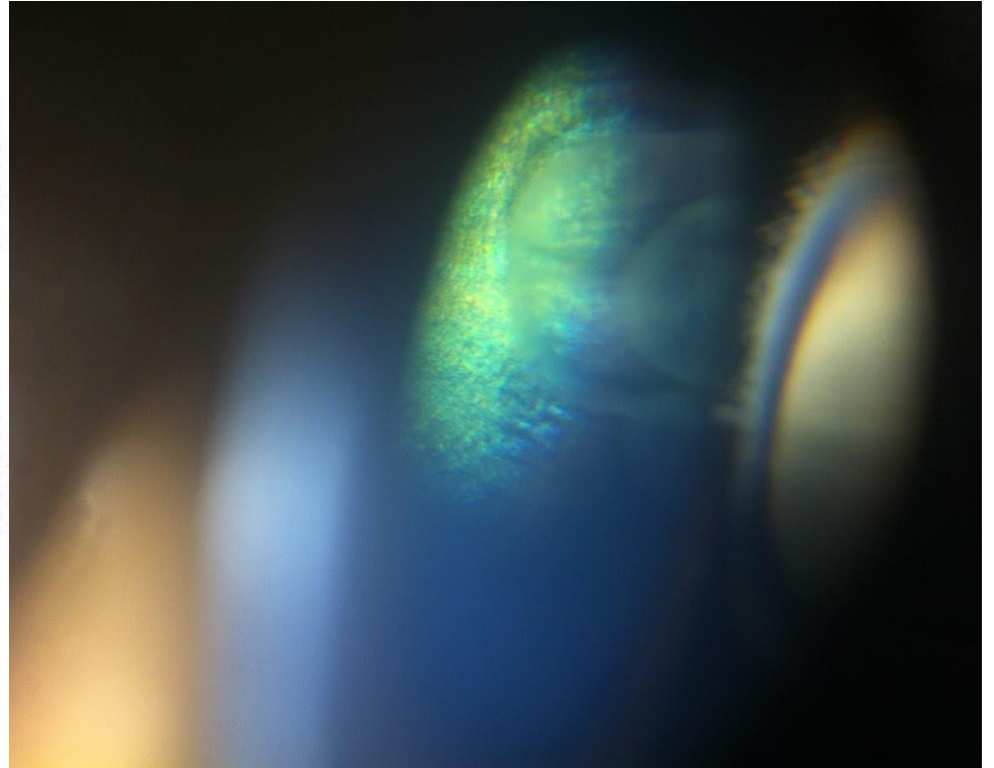
The background of the slide is a blurred, artistic image of an equine eye. The eye is the central focus, showing a mix of green, blue, and yellowish-brown tones, likely representing the iris and surrounding structures. The overall effect is soft and ethereal, with a dark, almost black background that makes the eye's colors stand out.

Imaging the equine vitreous

Vitreous

Start at vitreal base, 4 angles

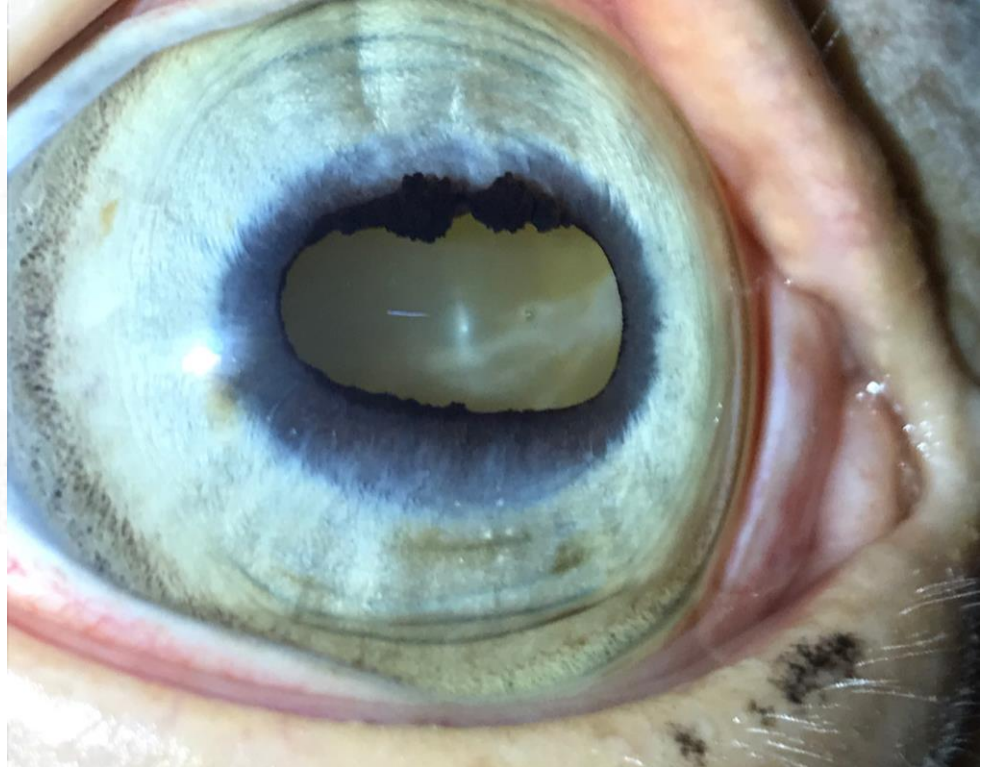
Video often helpful to document opacities



Vitreous

Start at vitreal base, 4 angles

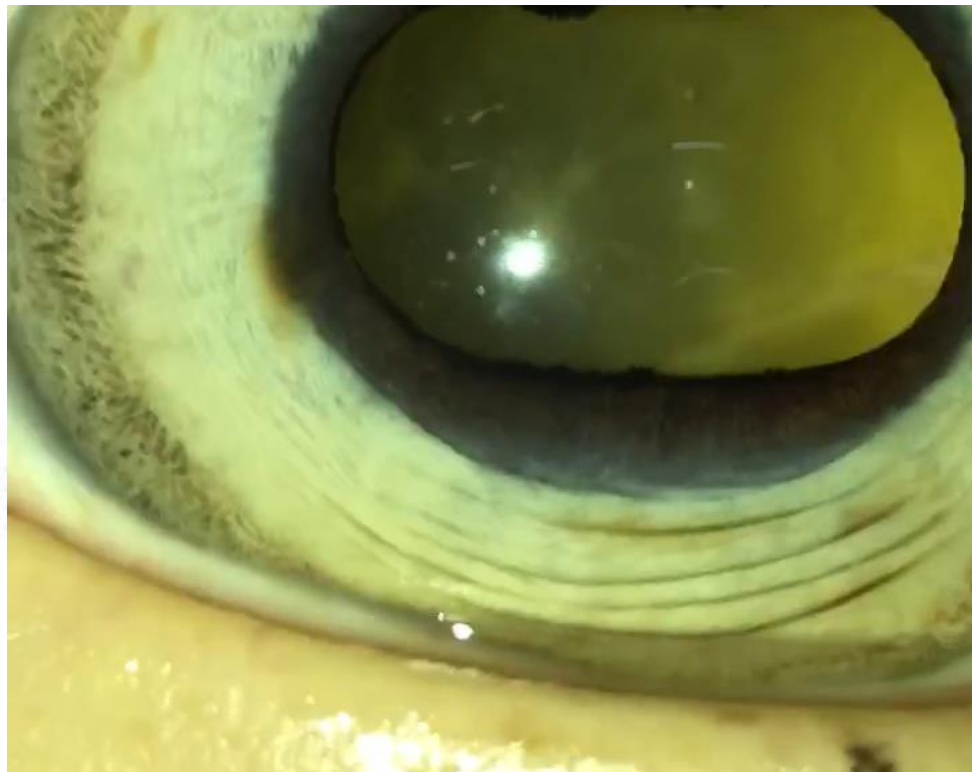
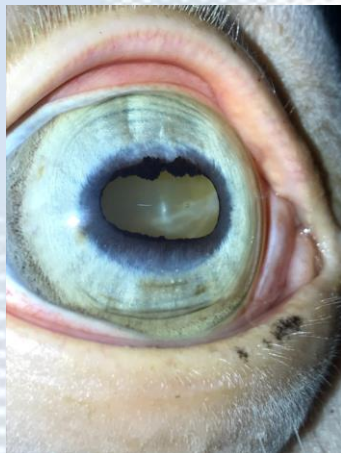
Video often helpful to document opacities




Vitreous

Start at vitreal base, 4 angles

Video often helpful to document opacities







Imaging the equine fundus

November 12, 1704; Jean Méry presents to the French Royal Academy of Sciences

*Jean Méry had reported to the Academy the observation that, by **submerging the head of a living cat in water**, one provoked dilatation of the pupils, which could not be reduced by light. **In this way, the elements of the fundus oculi are rendered visible.** That occurs, according to Méry, by flattening the irregularities of the surface of the cornea by contact with water. Méry's memoir is without question the **first publication**, not only of the **visualization of the elements of the fundus oculi**, but also of the neutralization of corneal dioptric power of a living eye in a liquid, which is an essential part of optical contact systems*

The solution?



Fundoscopy – seeing the retina

*On March 20, 1709, Philippe de La Hire pointed out that this was due to the abolition of the corneal refraction. Méry's experiment of eye immersion for fundus visualization was repeated and supplemented later in humans: in 1845 by Adolf Kussmaul, in 1851 by Johann Nepomuk Czermak for the construction of the orthoscope, and in **1891** by **Oswald Gerloff**, who took the earliest successful fundus photography.*

Fundoscopy – seeing the retina

*On March 20, 1709, Philippe de La Hire pointed out that this was due to the abolition of the corneal refraction. Méry's experiment of eye immersion for fundus visualization was repeated and supplemented later in humans: in 1845 by Adolf Kussmaul, in 1851 by Johann Nepomuk Czermak for the construction of the orthoscope, and in **1891** by **Oswald Gerloff, who took the earliest successful fundus photography... or did he***

CANADA
MEDICAL JOURNAL

AND
Monthly Record
 OF
 MEDICAL AND SURGICAL SCIENCE.

EDITED BY

GEORGE E. FENWICK, M.D.,

PHYSICIAN TO THE MONTREAL GENERAL HOSPITAL; PHYSICIAN TO THE MONTREAL DISPENSARY
 AND INFIRMARY FOR DISEASES OF WOMEN AND CHILDREN; DEMONSTRATOR
 OF ANATOMY MCGILL UNIVERSITY;

AND

FRANCIS WAYLAND CAMPBELL, M.D.,

LICENTIATE OF THE ROYAL COLLEGE OF PHYSICIANS, LONDON, ENGLAND; PHYSICIAN TO THE
 MONTREAL DISPENSARY AND INFIRMARY FOR DISEASES OF
 WOMEN AND CHILDREN.

VOL. I.



MONTREAL:

DAWSON BROTHERS No. 23 GREAT ST. JAMES STREET;

BALLIERE BROTHERS, LONDON, PARIS, AND NEW YORK.

1865.

JOHN LOVELL, PRINTER.

*A new Ophthalmoscope for photographing the posterior internal surface
 of the living eye.* By A. M. ROSEBRUGH, M.D., Toronto.

CONSTRUCTION:—THE TUBES.

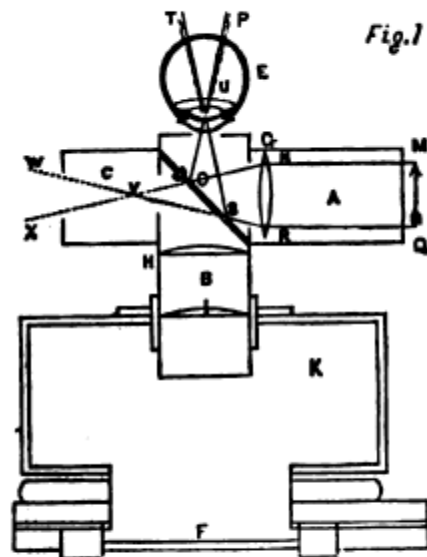


FIG. 1.

This instrument consists of a small photographic camera, to which are adapted two brass tubes (A and B) which meet each other at right angles (fig. 1), $1\frac{1}{2}$ inch in diameter, being respectively 4 and $2\frac{1}{2}$ inches in length. The longer tube B moves freely in the aperture of the camera, and the shorter tube A is turned towards the source of light.

A tube of the same width C, $1\frac{1}{2}$ inch in length, is joined to the side

CANADA
MEDICAL JOURNAL

AND
Monthly Record
OF
MEDICAL AND SURGICAL SCIENCE.

EDITED BY

GEORGE E. FENWICK, M.D.,

PHYSICIAN TO THE MONTREAL GENERAL HOSPITAL; PHYSICIAN TO THE MONTREAL DISPENSARY
AND INFIRMARY FOR DISEASES OF WOMEN AND CHILDREN; DEMONSTRATOR
OF ANATOMY McGill University;

AND

FRANCIS WAYLAND CAMPBELL, M.D.,

LICENTIATE OF THE ROYAL COLLEGE OF PHYSICIANS, LONDON, ENGLAND; PHYSICIAN TO THE
MONTREAL DISPENSARY AND INFIRMARY FOR DISEASES OF
WOMEN AND CHILDREN.

VOL. I.



MONTREAL:


DAWSON BROTHERS No. 23 GREAT ST. JAMES STREET;

BALLIERE BROTHERS, LONDON, PARIS, AND NEW YORK.

1865.

JOHN LOVELL, PRINTER.

AS AN OPHTHALMOSCOPE.



The position of the instrument when the light is supplied by a lamp:—1, the camera; 2, camera tube; 3, illuminating tube; 4, diaphragm with central aperture; 5, slide with ground glass, 6, glass chimney of lamp; 7, brass tube four inches in diameter, which acts as a shade, and from which projects 8, a brass collar opposite the flame of the lamp, and to which is adapted 3, the illuminating tube of the instrument; 9, upright of the lamp stand; 10, eye-piece containing a camera lens of three inch focus to be adapted to the free extremity of the camera tube: when the eye-piece is used the camera is dispensed with.

CANADA
MEDICAL JOURNAL

AND
Monthly Record

OF
MEDICAL AND SURGICAL SCIENCE.

EDITED BY

GEORGE E. FENWICK, M.D.,

PHYSICIAN TO THE MONTREAL GENERAL HOSPITAL; PHYSICIAN TO THE MONTREAL DISPENSARY
AND INFIRMARY FOR DISEASES OF WOMEN AND CHILDREN; DEMONSTRATOR
OF ANATOMY MONTREAL UNIVERSITY.

AND

FRANCIS WAYLAND CAMPBELL, M.D.,

LICENTIATE OF THE ROYAL COLLEGE OF PHYSICIANS, LONDON, ENGLAND; PHYSICIAN TO THE
MONTREAL DISPENSARY AND INFIRMARY FOR DISEASES OF
WOMEN AND CHILDREN.

VOL. I.



MONTREAL:


DAWSON BROTHERS No. 23 GREAT ST. JAMES STREET;
BALLIÈRE BROTHERS, LONDON, PARIS, AND NEW YORK.
1865.

JOHN LOVELL, PRINTER.

Digitized by Google



AS AN OPHTHALMOSCOPE.



The position of the instrument when the light is supplied by a lamp:—1, the camera; 2, camera tube; 3, illuminating tube; 4, diaphragm with central aperture; 5, slide with ground glass, 6, glass chimney of lamp; 7, brass tube four inches in diameter, which acts as a shade, and from which projects 8, a brass collar opposite the flame of the lamp, and to which is adapted 3, the illuminating tube of the instrument; 9, upright of the lamp stand; 10, eye-piece containing a camera lens of three inch focus to be adapted to the free extremity of the camera tube: when the eye-piece is used the camera is dispensed with.

Direct vs indirect ophthalmoscopy

Direct fundoscopy

Small FOV = greater detail

Doesn't like opacities in the visual axis

Need to be close to the cornea

Indirect fundoscopy

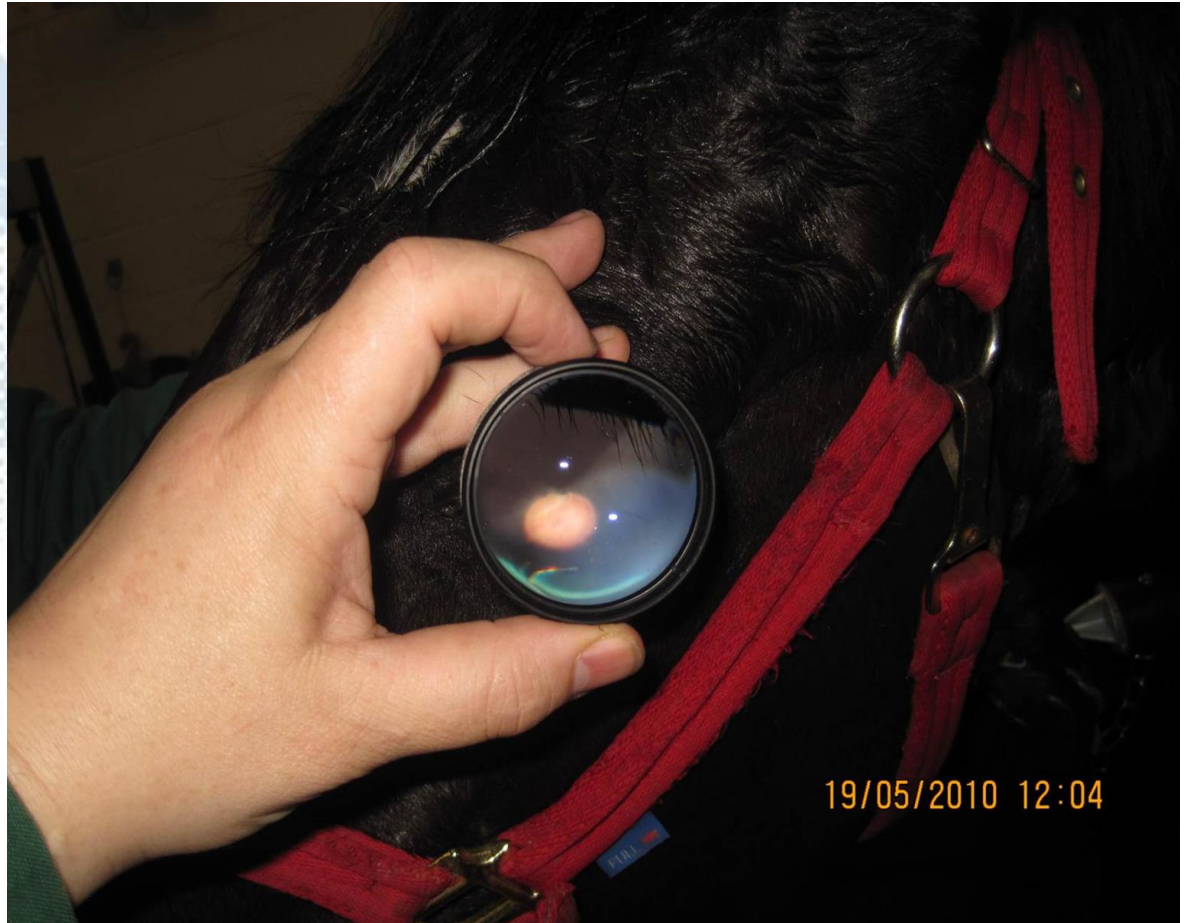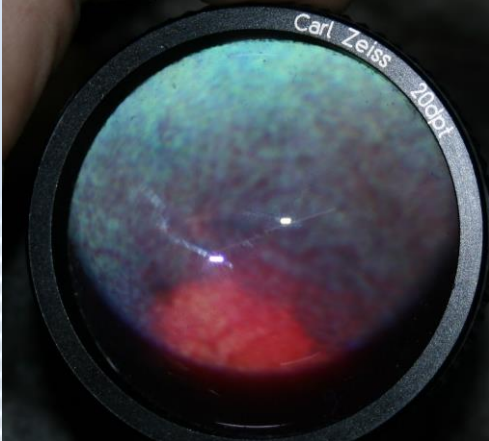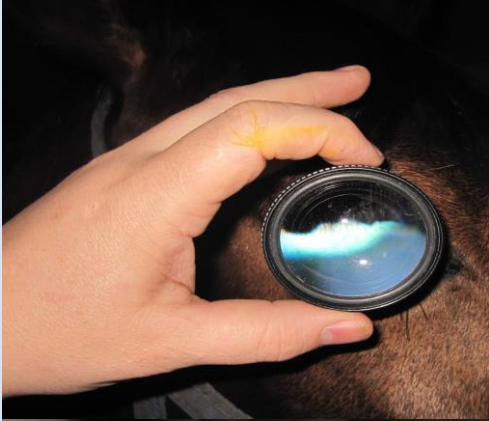Modality of choice in small animals – less widely used in equine

Wide FOV = less detail


Copes well with opacities in the visual axis

A distant technique


Indirect



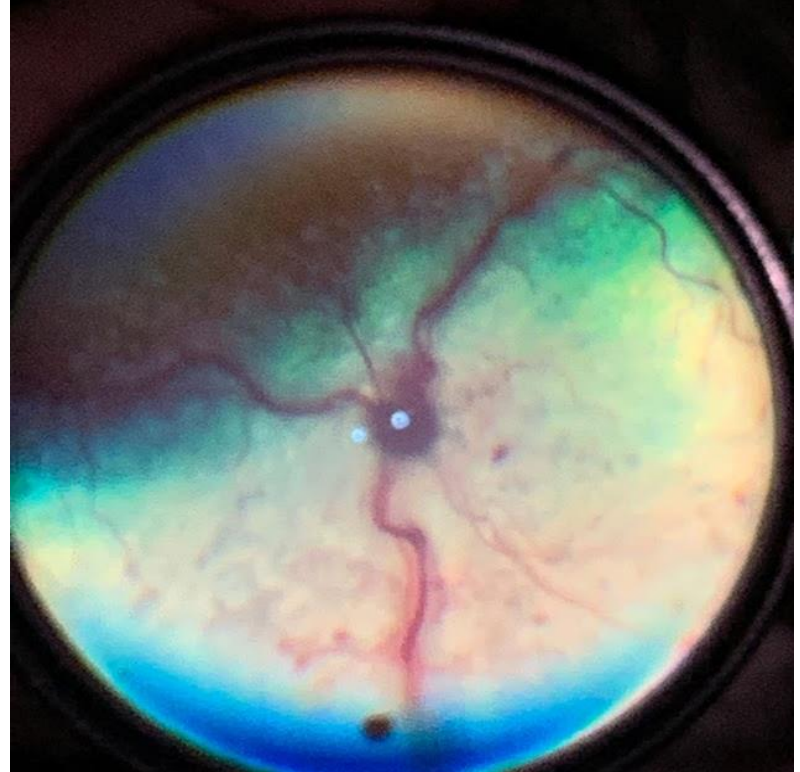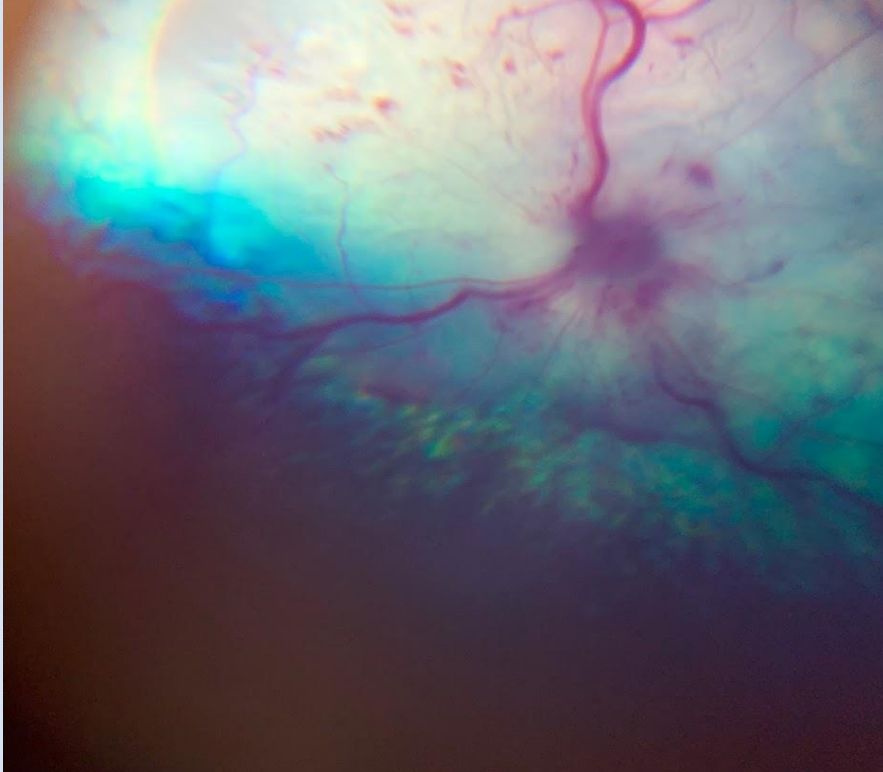
Guess the species



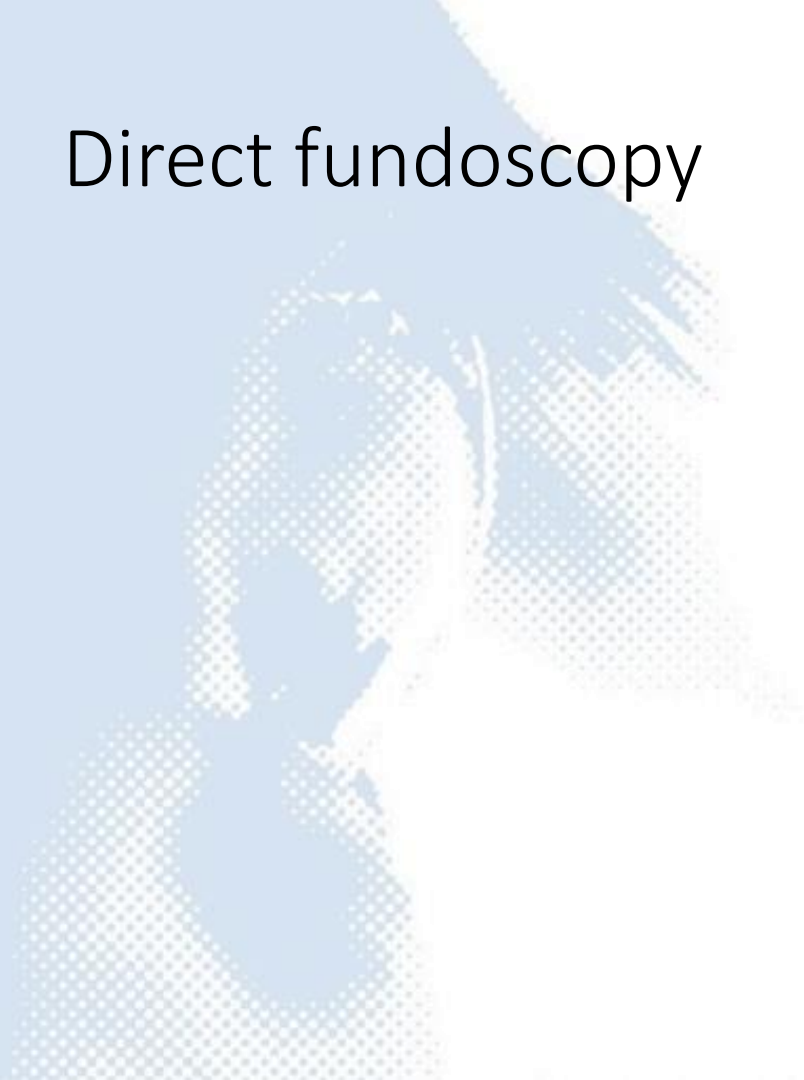
Guess the species



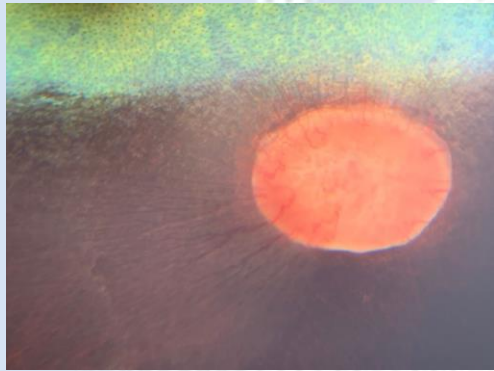
Field of view: determined by camera



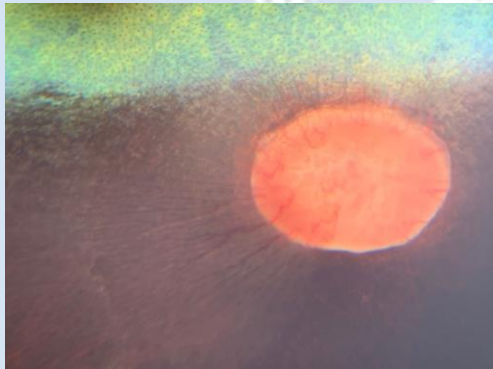
Direct funduscopy



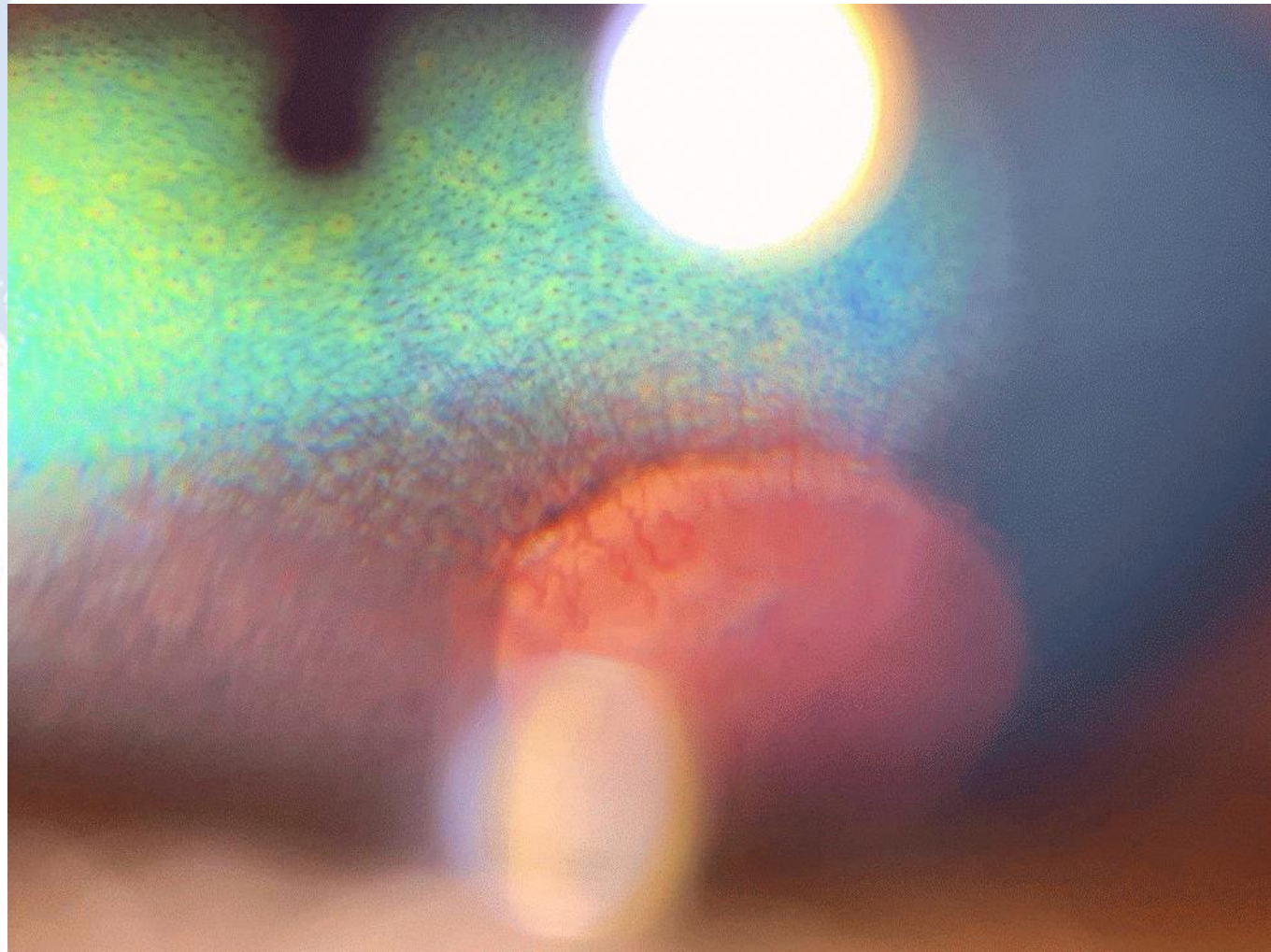
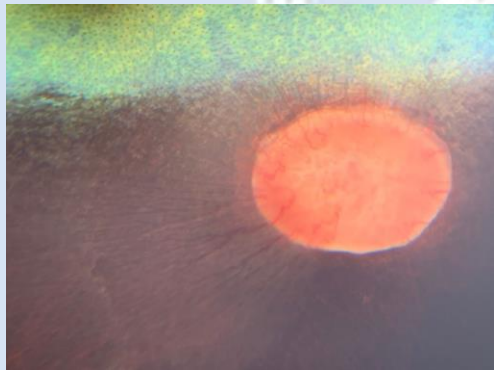
Tell a story

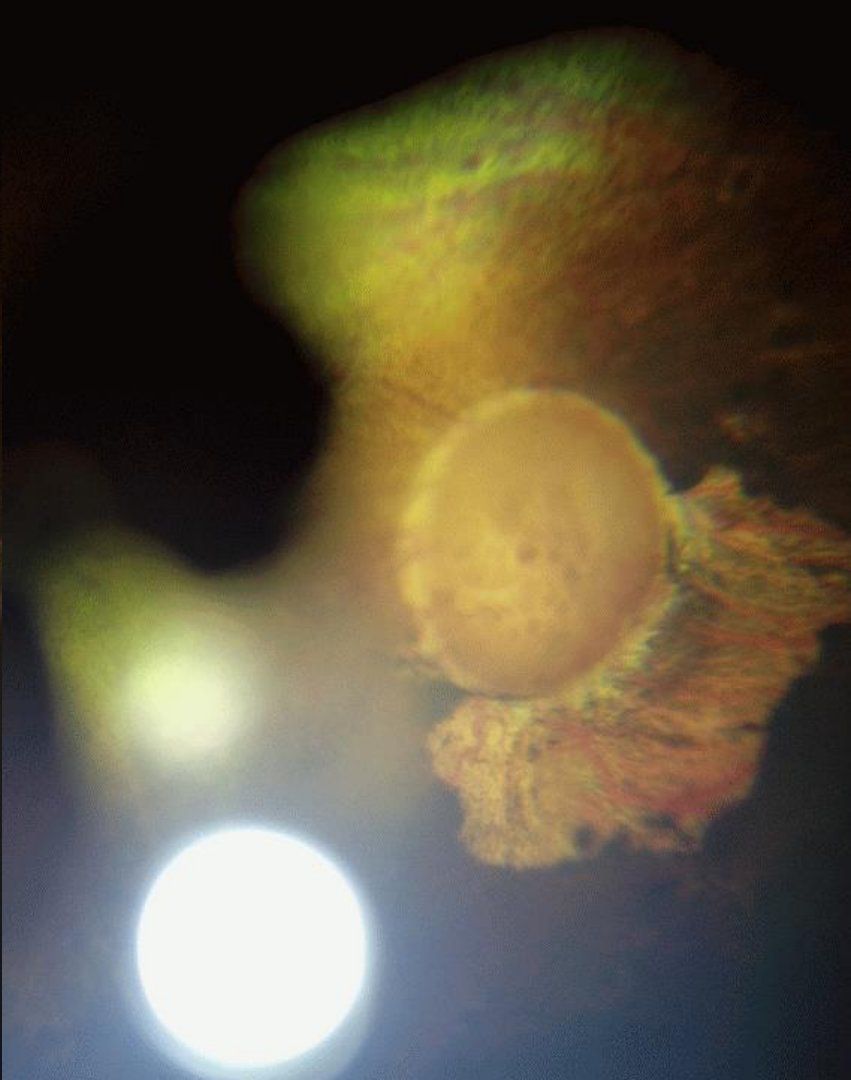
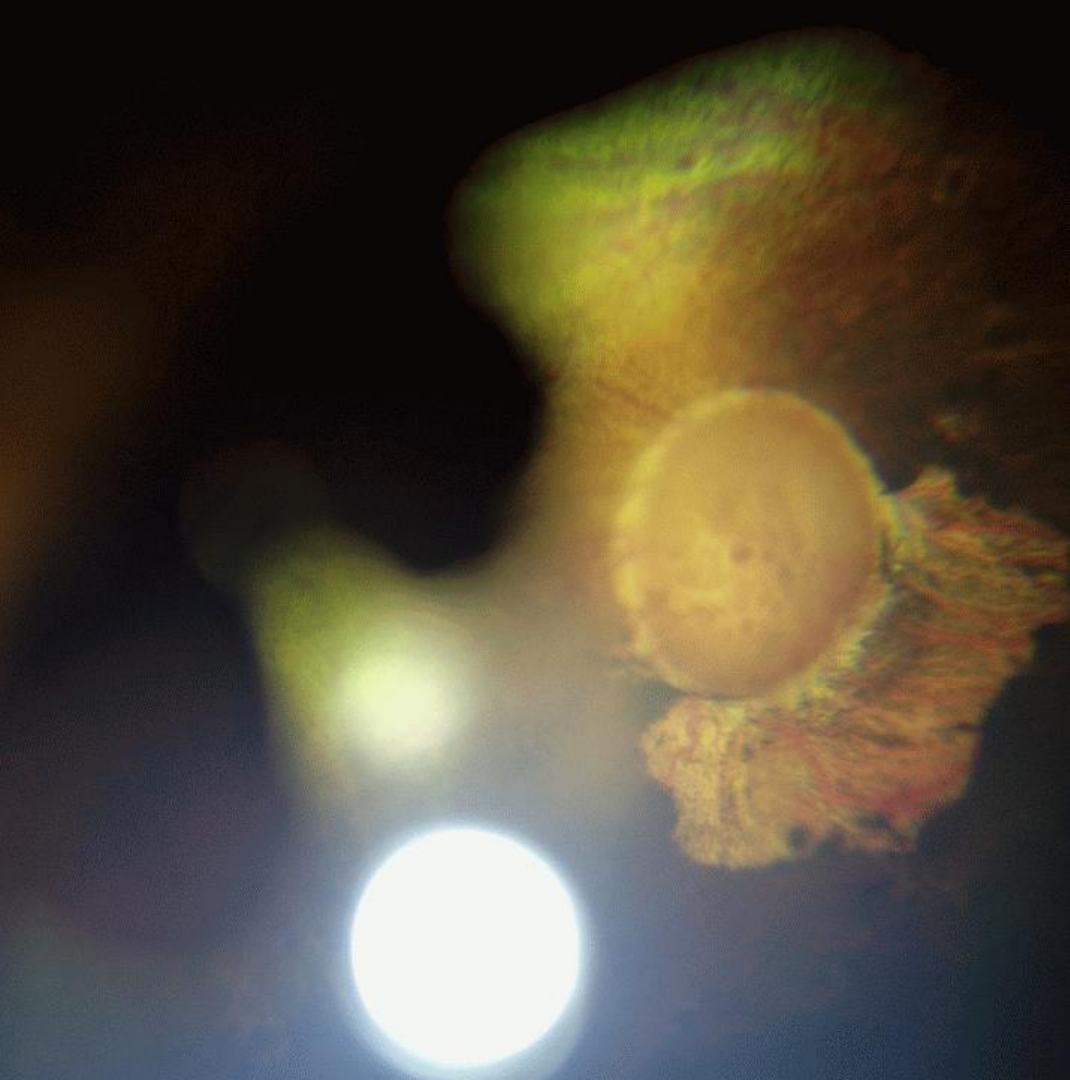

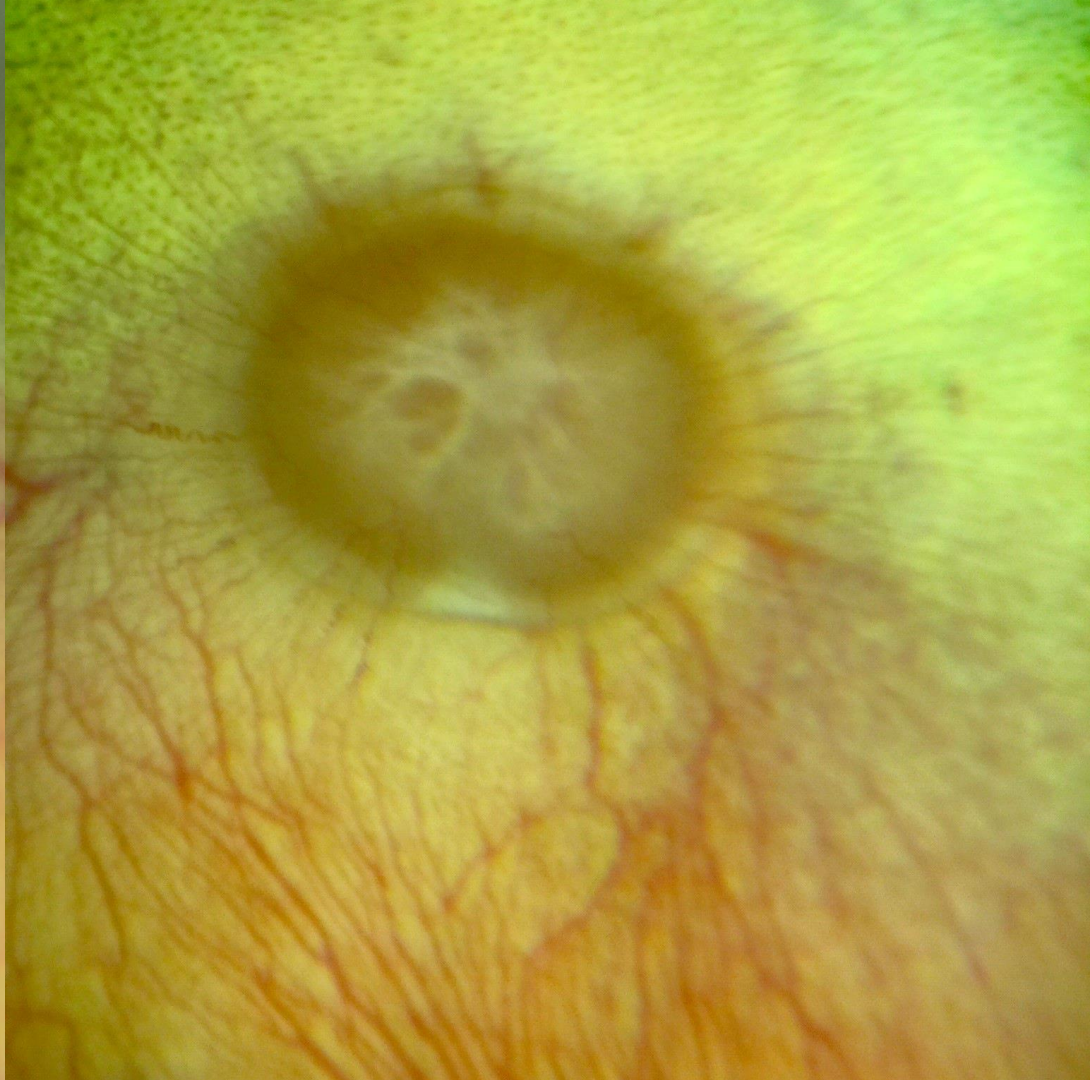
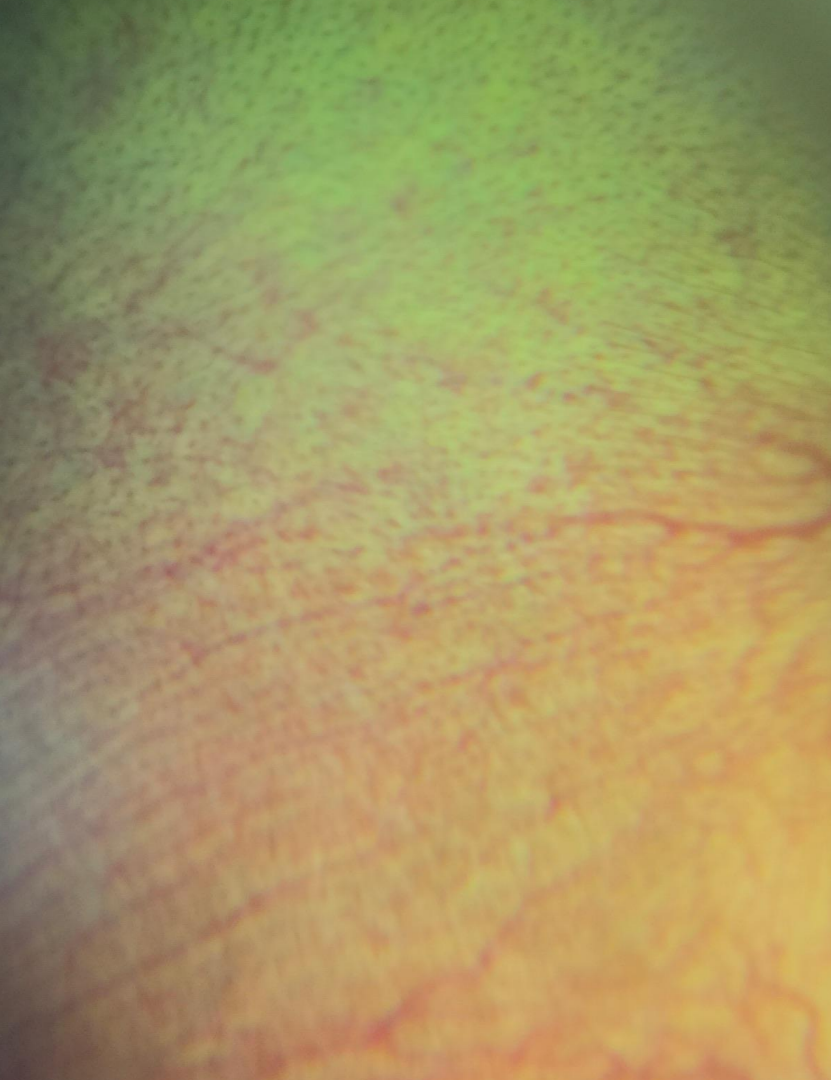Tell a story

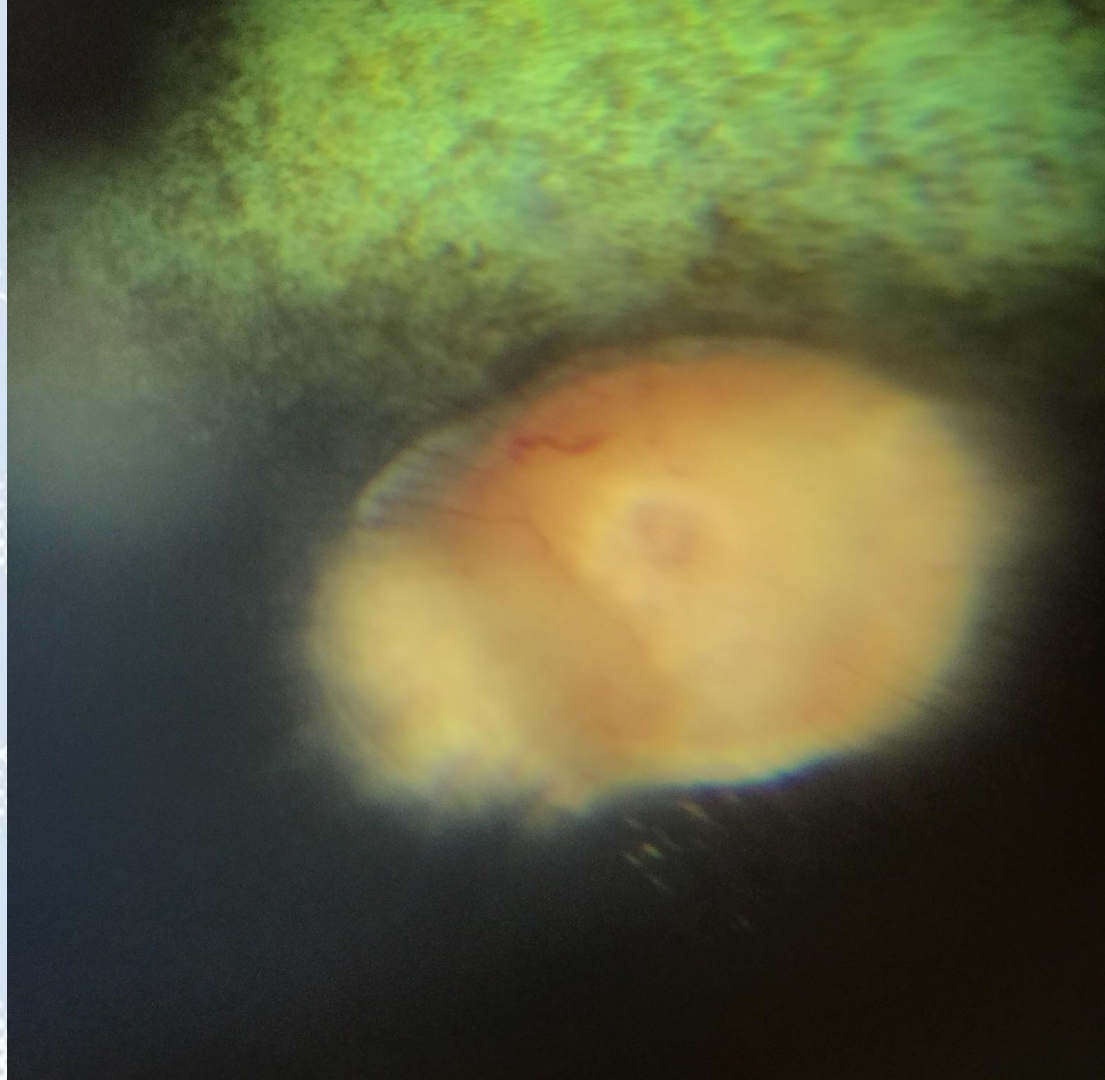


Tell a story



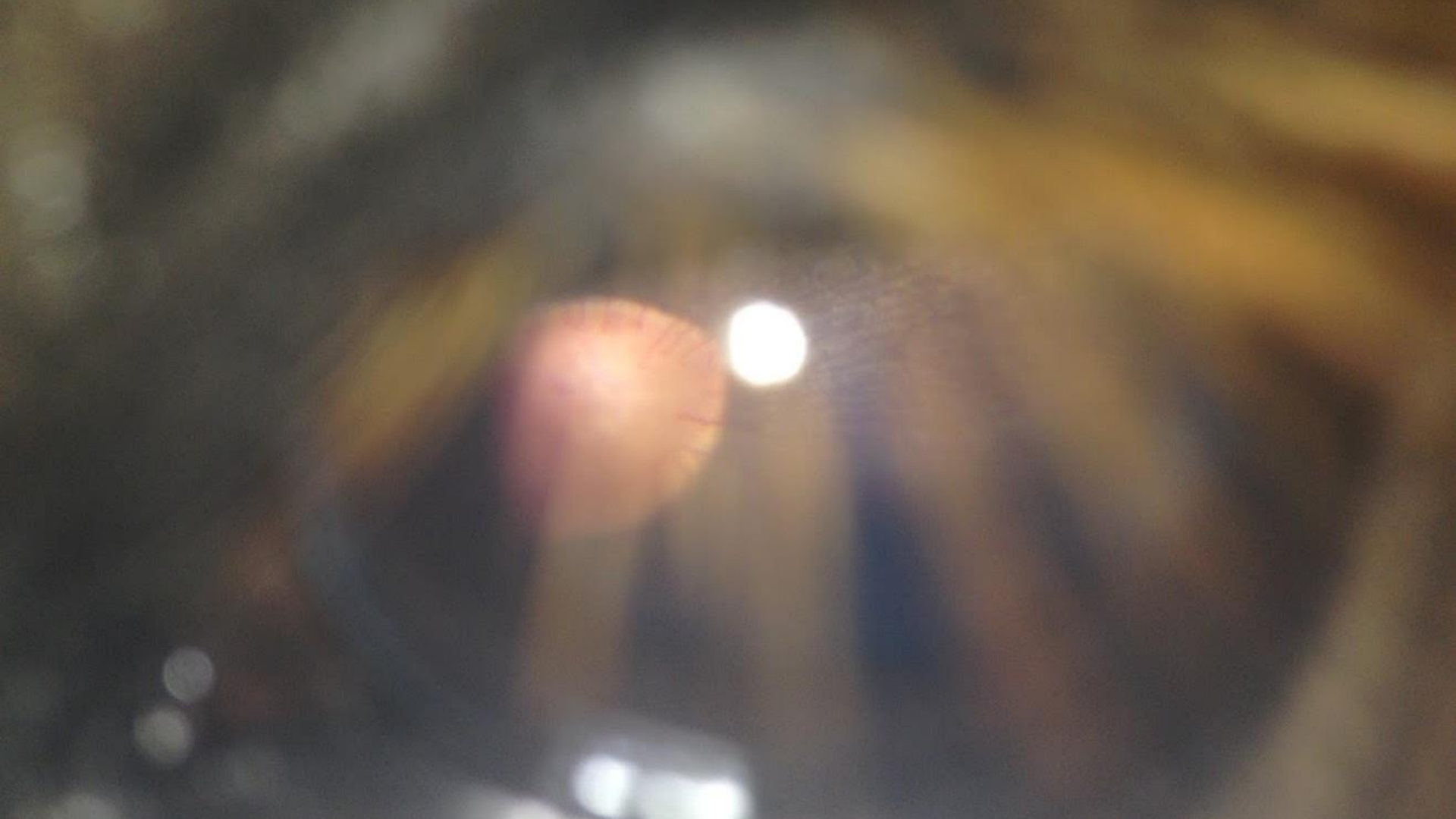







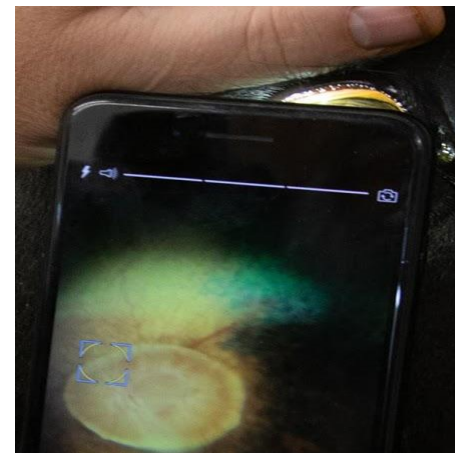
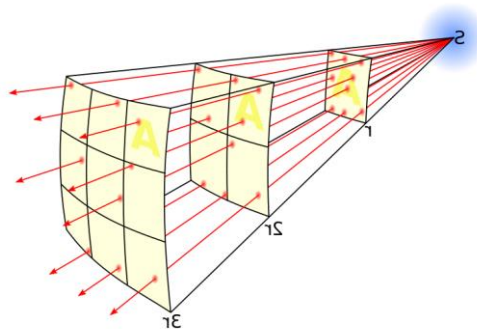

Technique





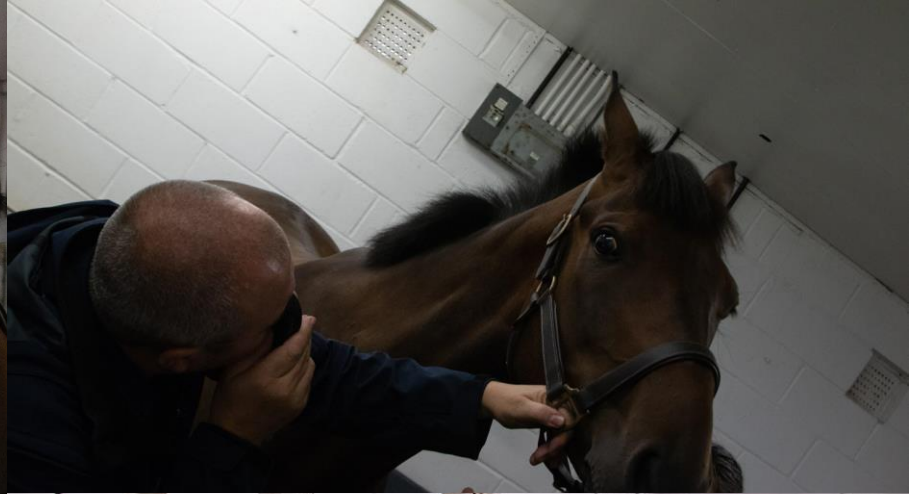FOR ATTENTION CONTACT
MEDICAL ENGINEERING
ROYAL LIVERPOOL UNIVERSITY HOSPITAL
TEL: 051-706 20078

Diffuser, app &/or physics to dim the light





The visual axis



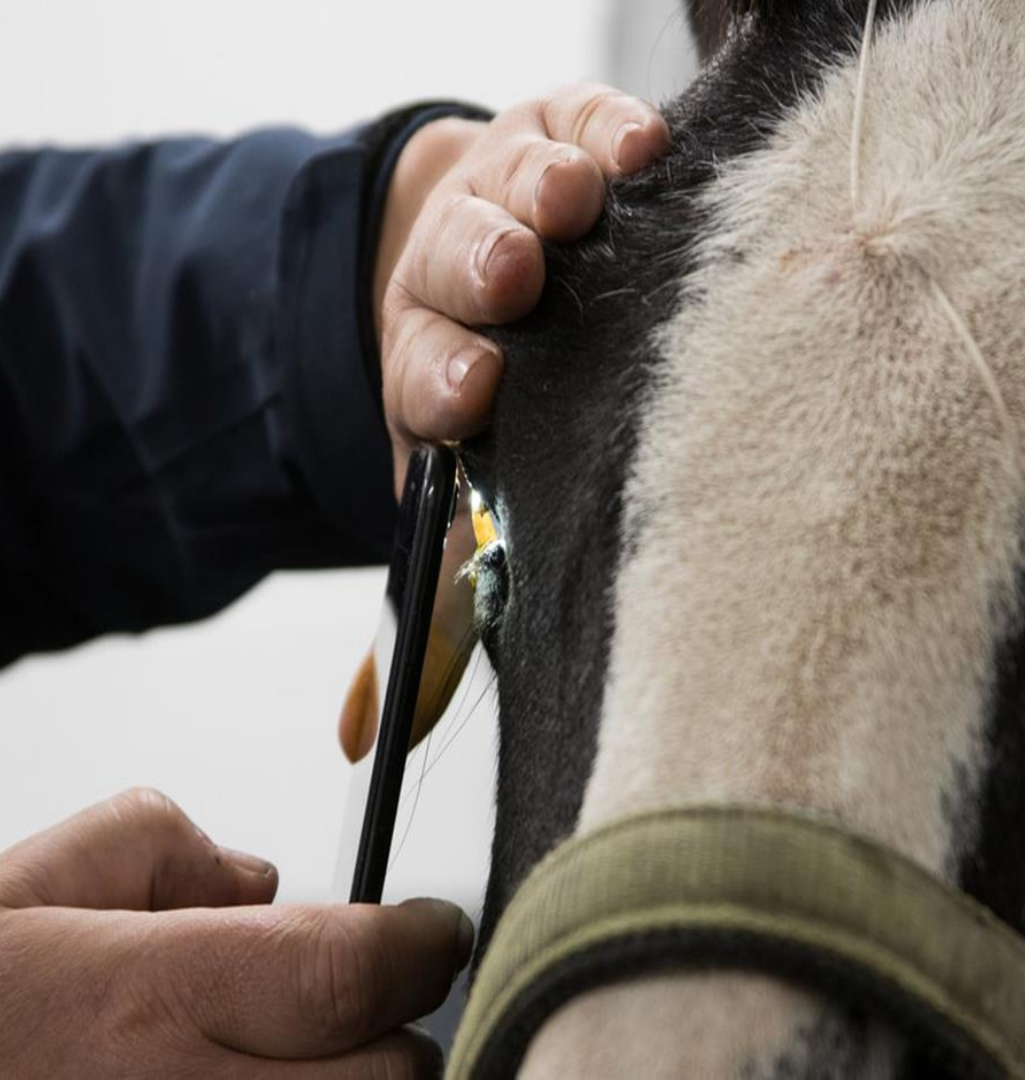

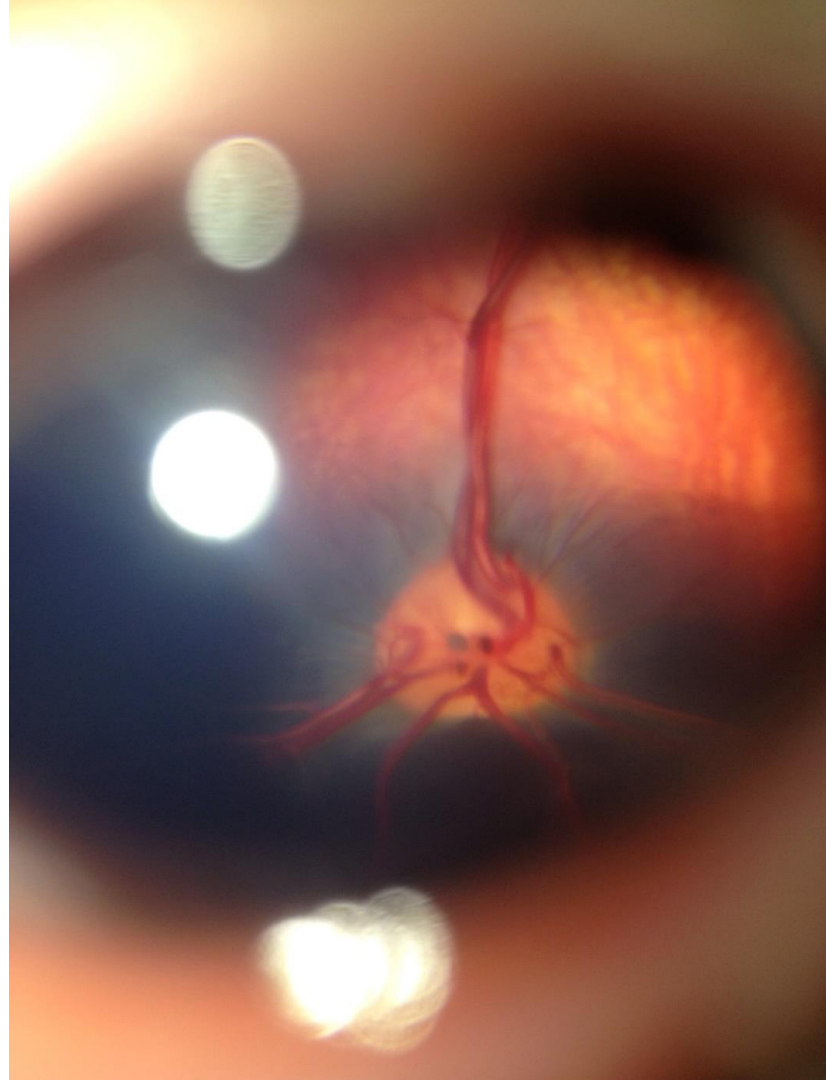

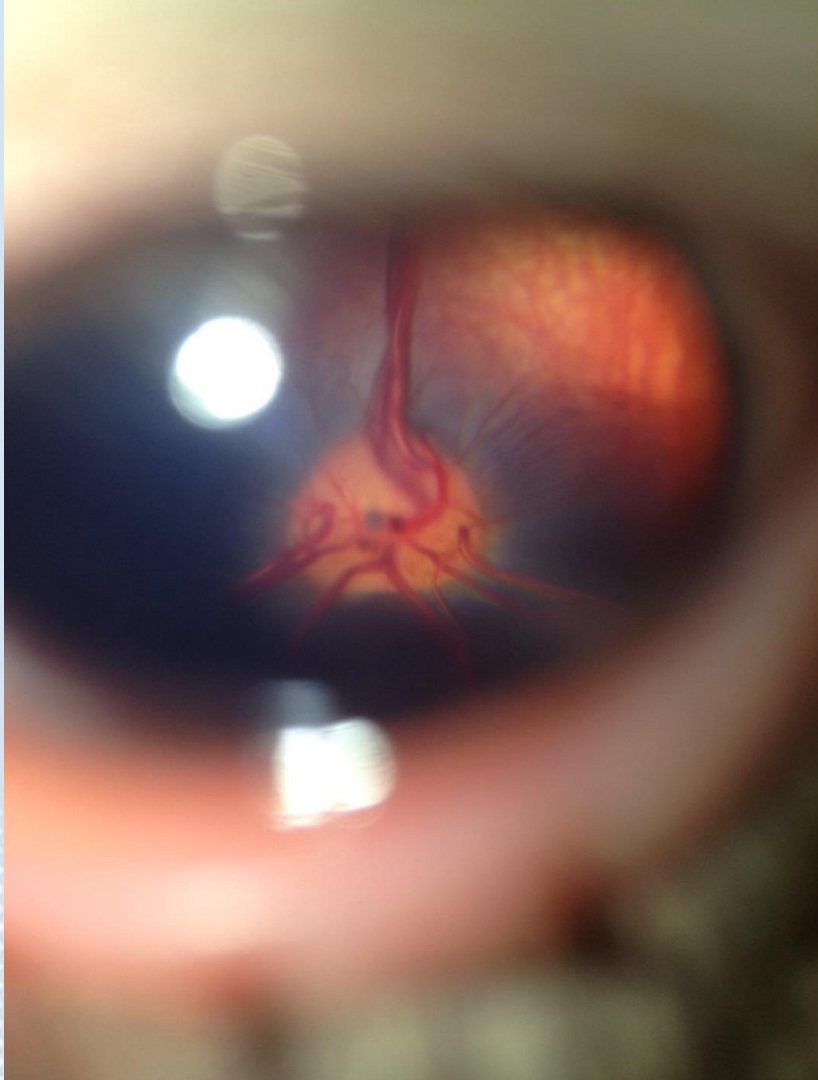
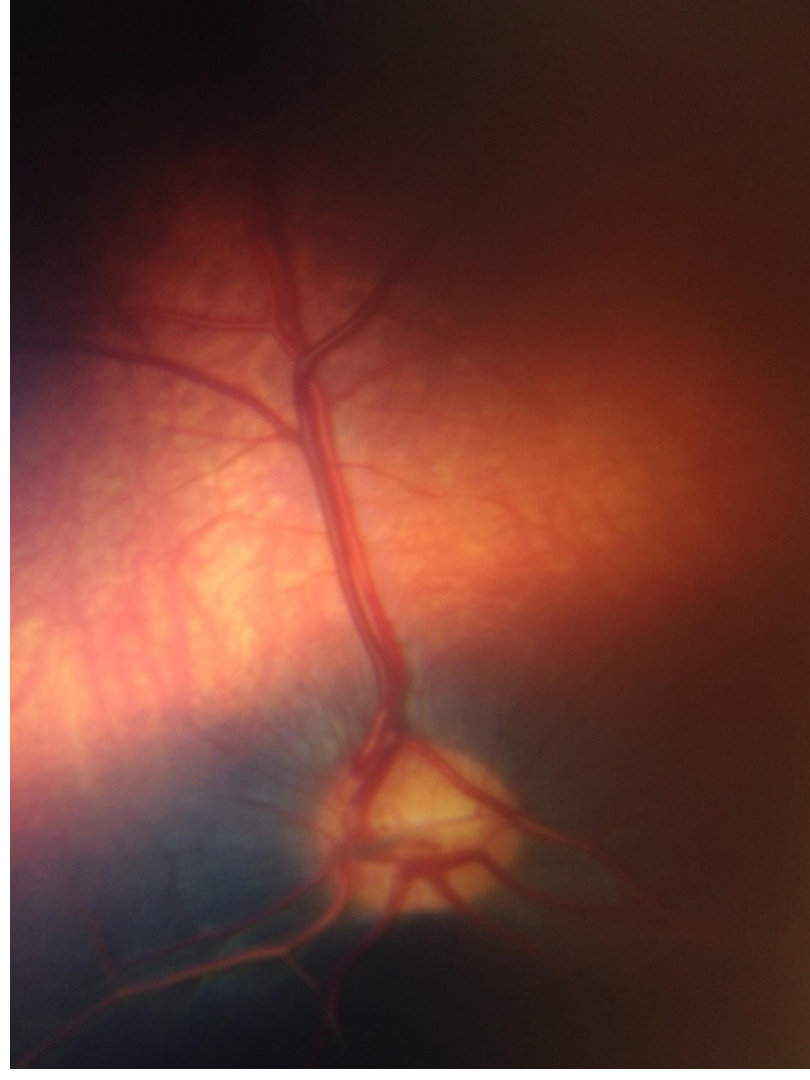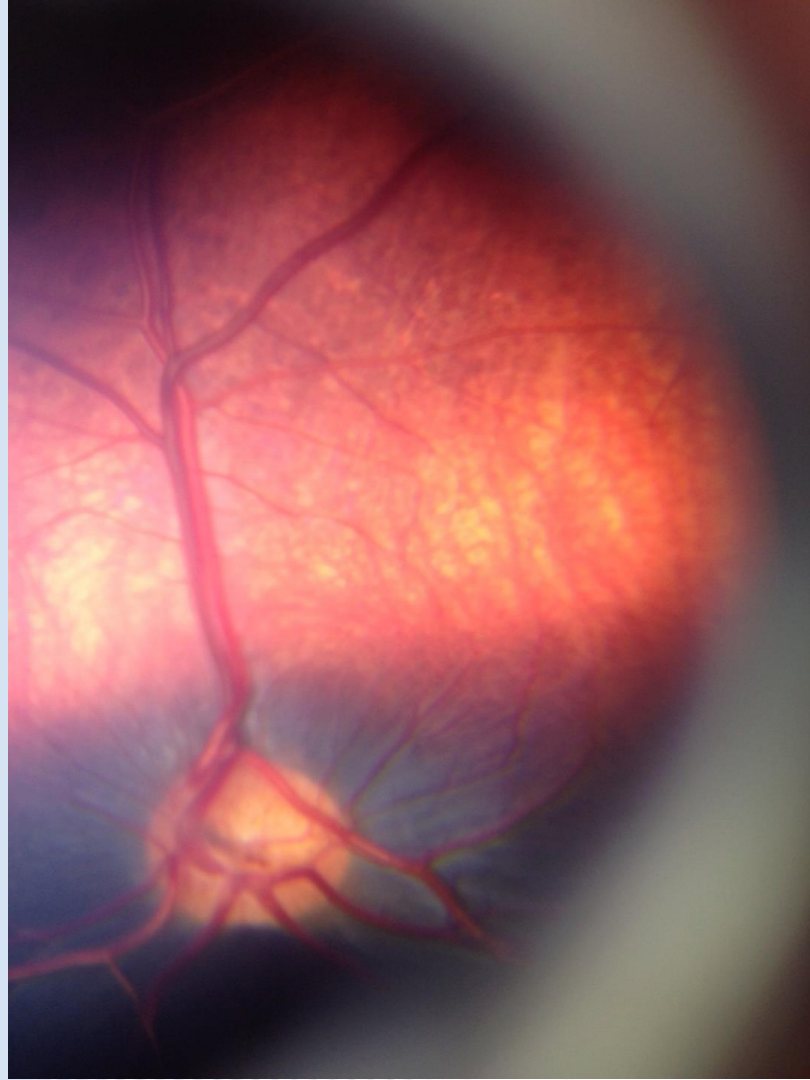
The fundus


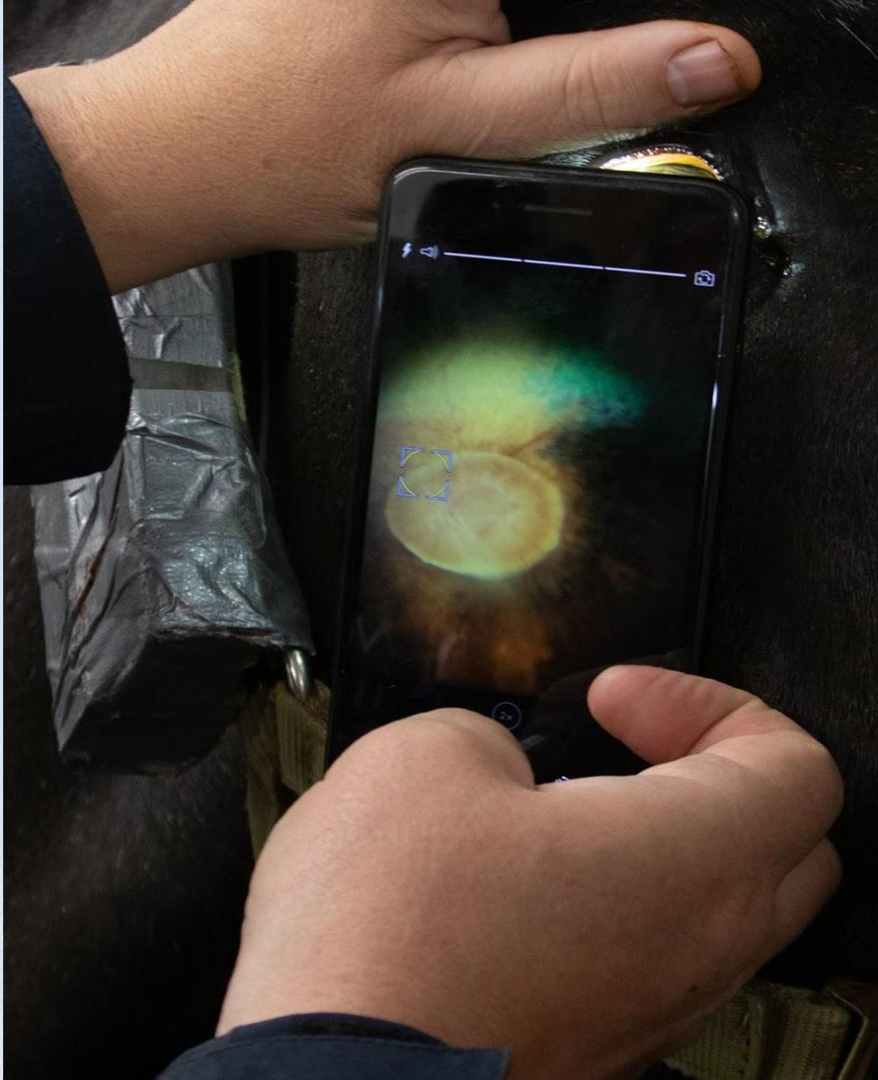

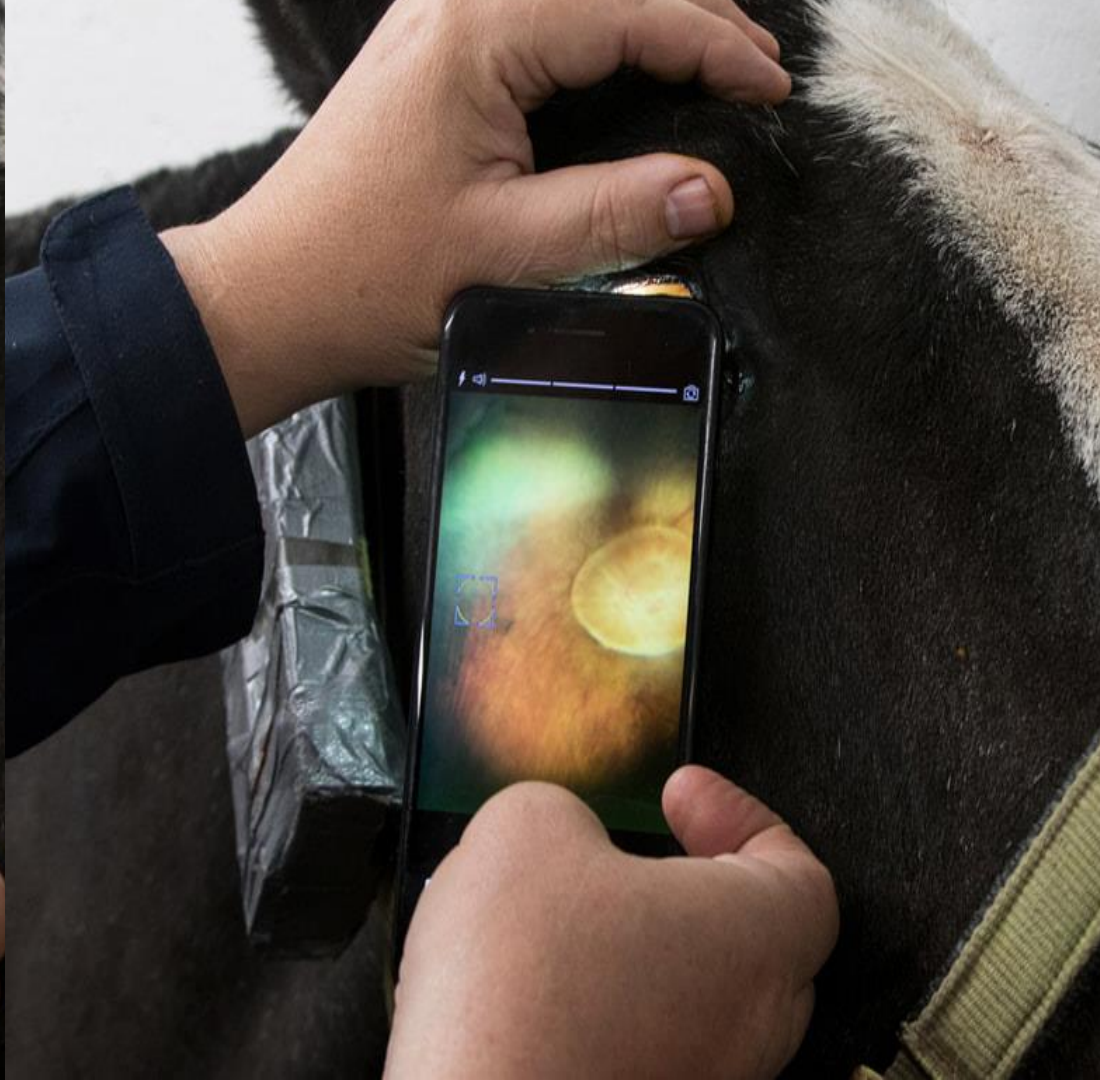
Equine
Eye Clinic





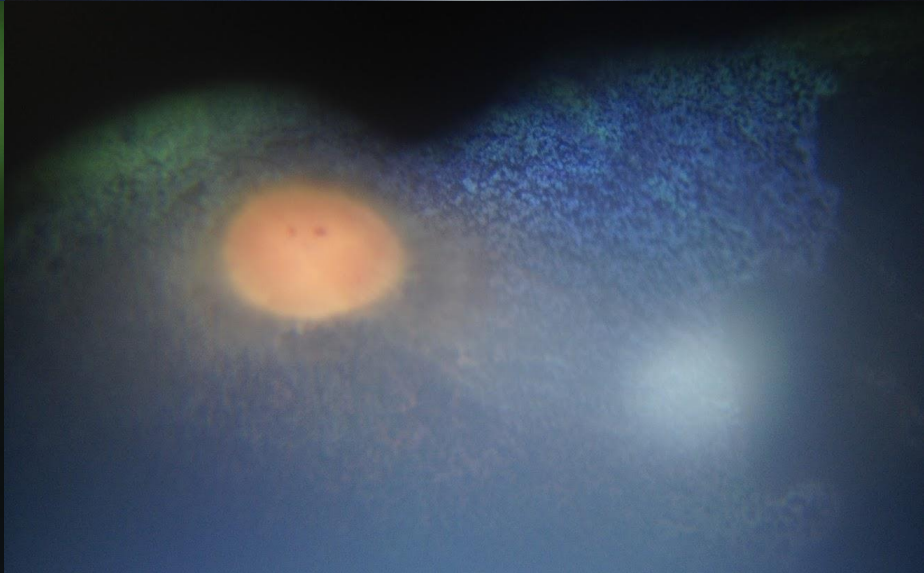
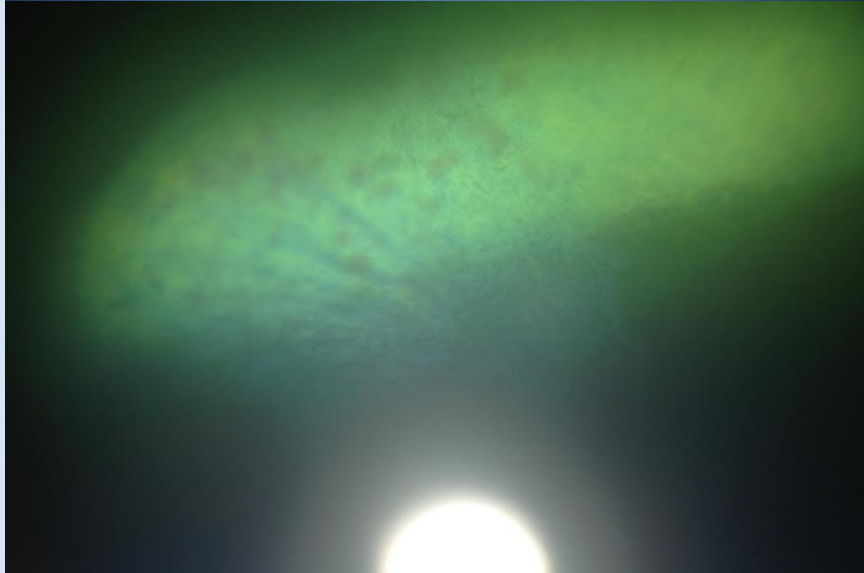
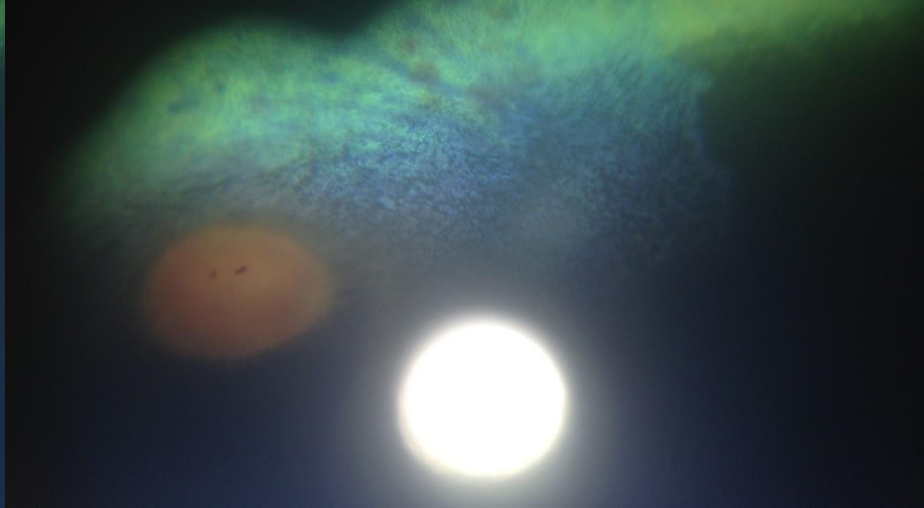
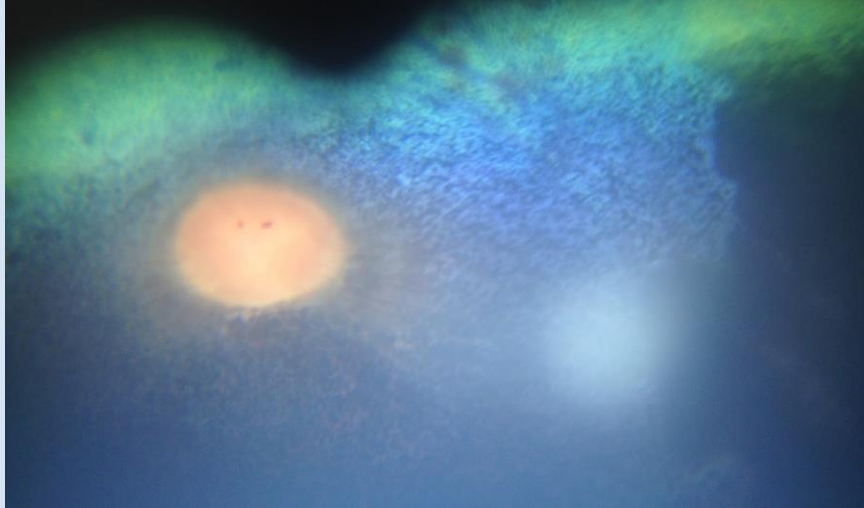











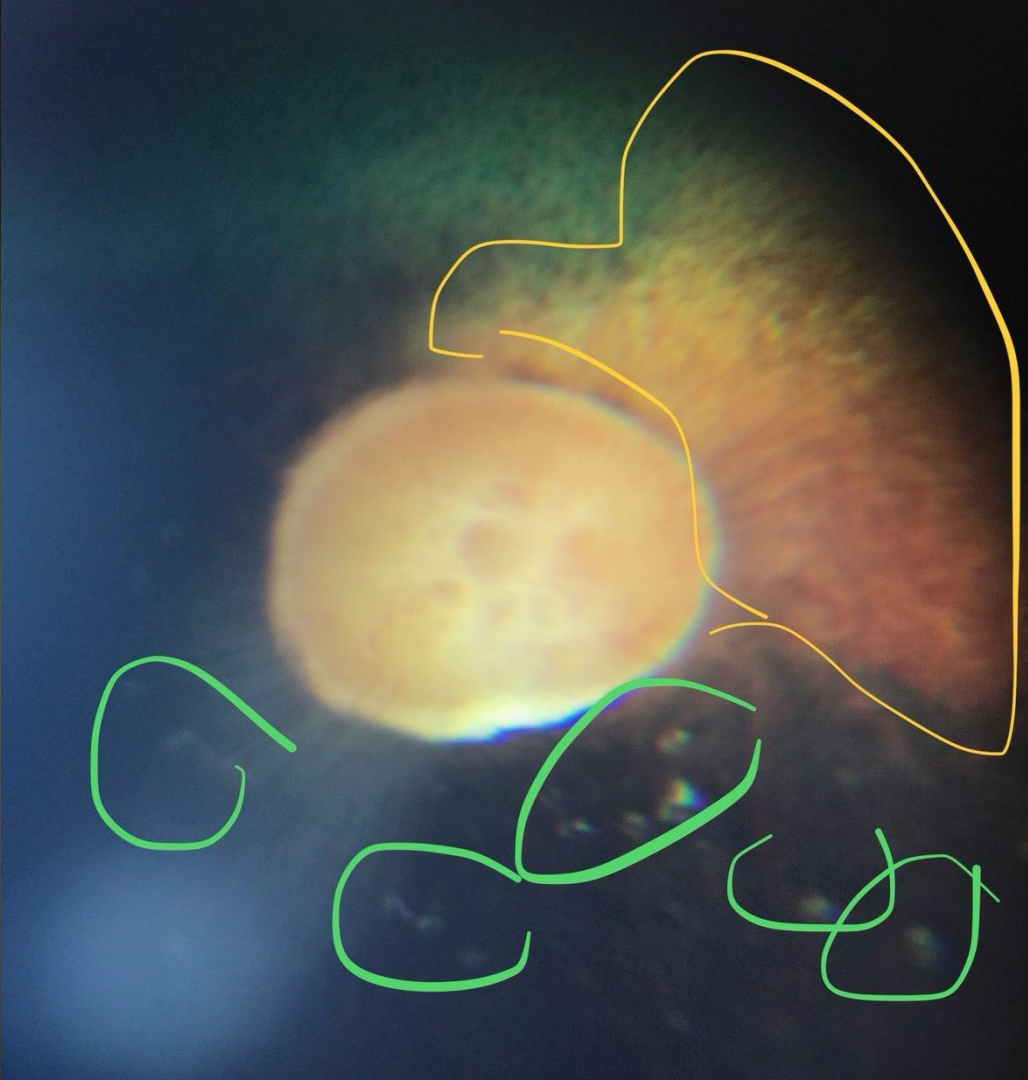
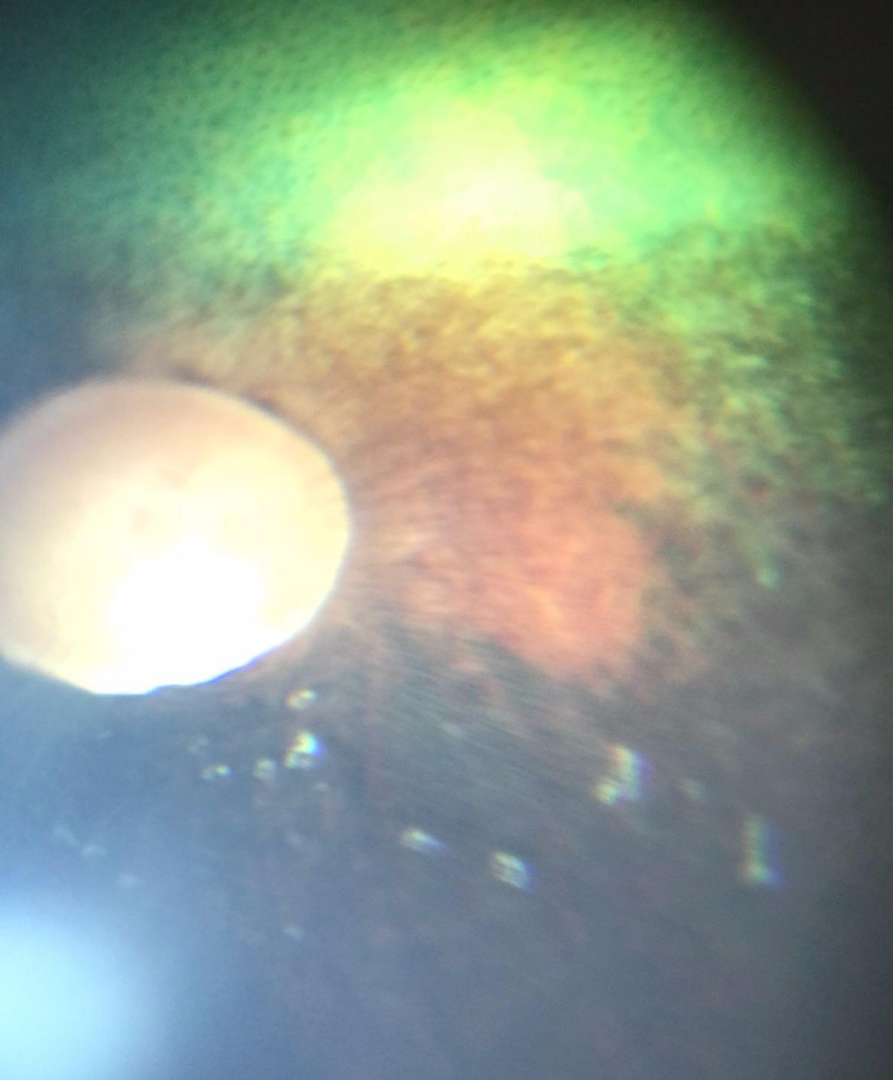


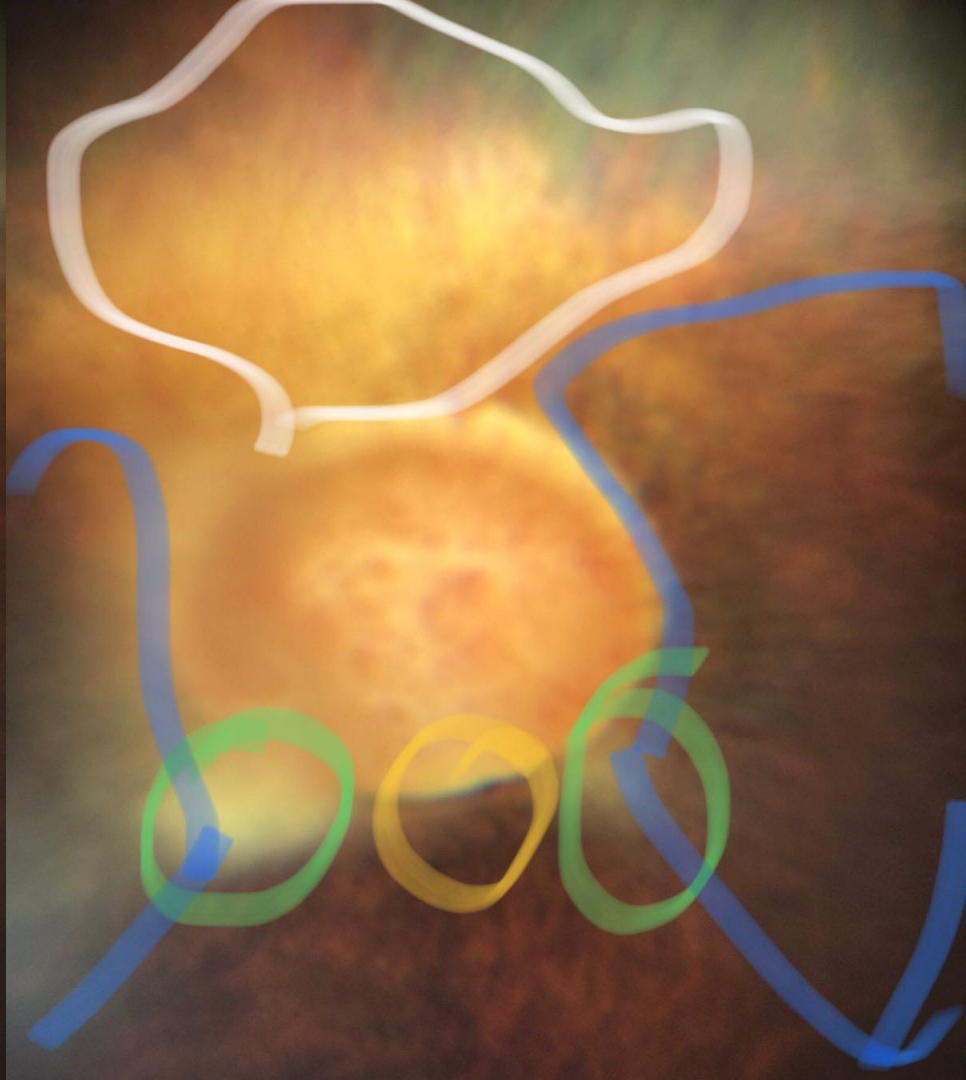
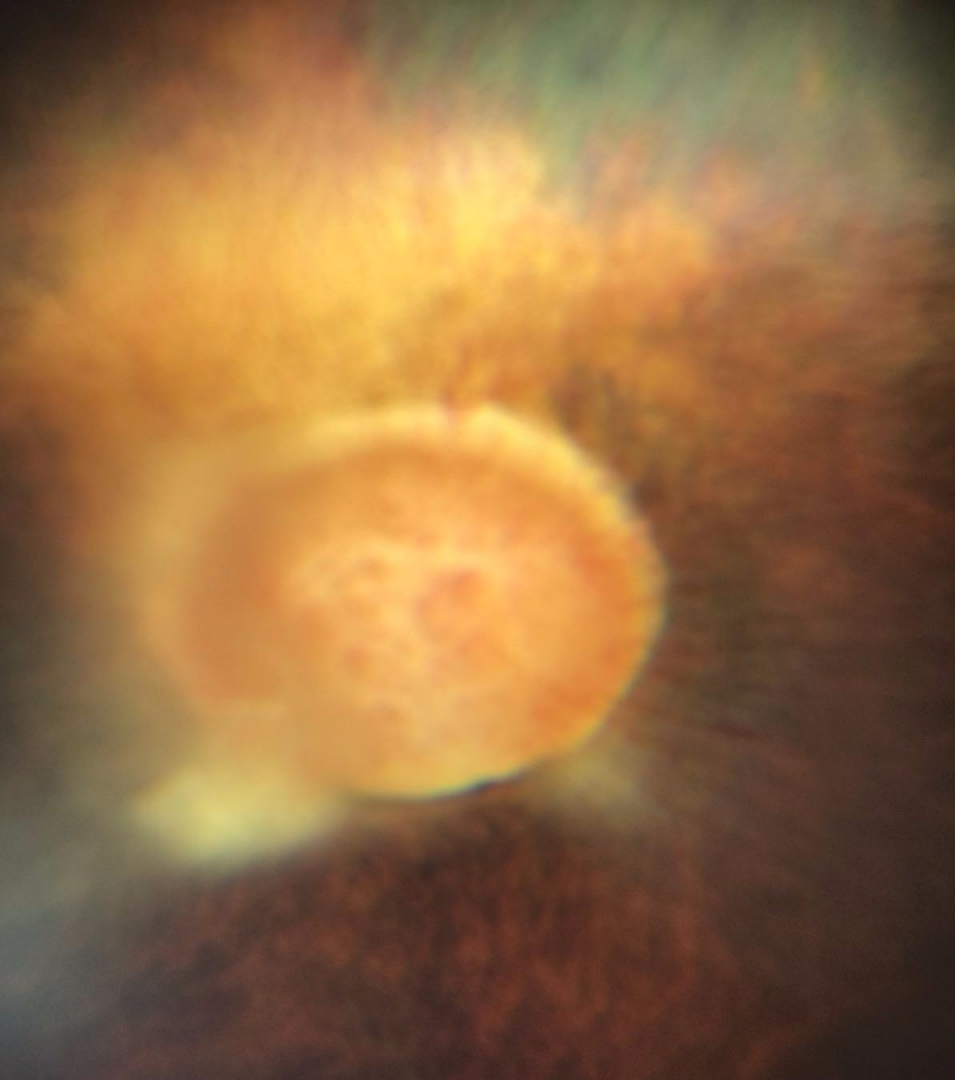


Manual focus & telephoto lens (iPhone Xsmax)



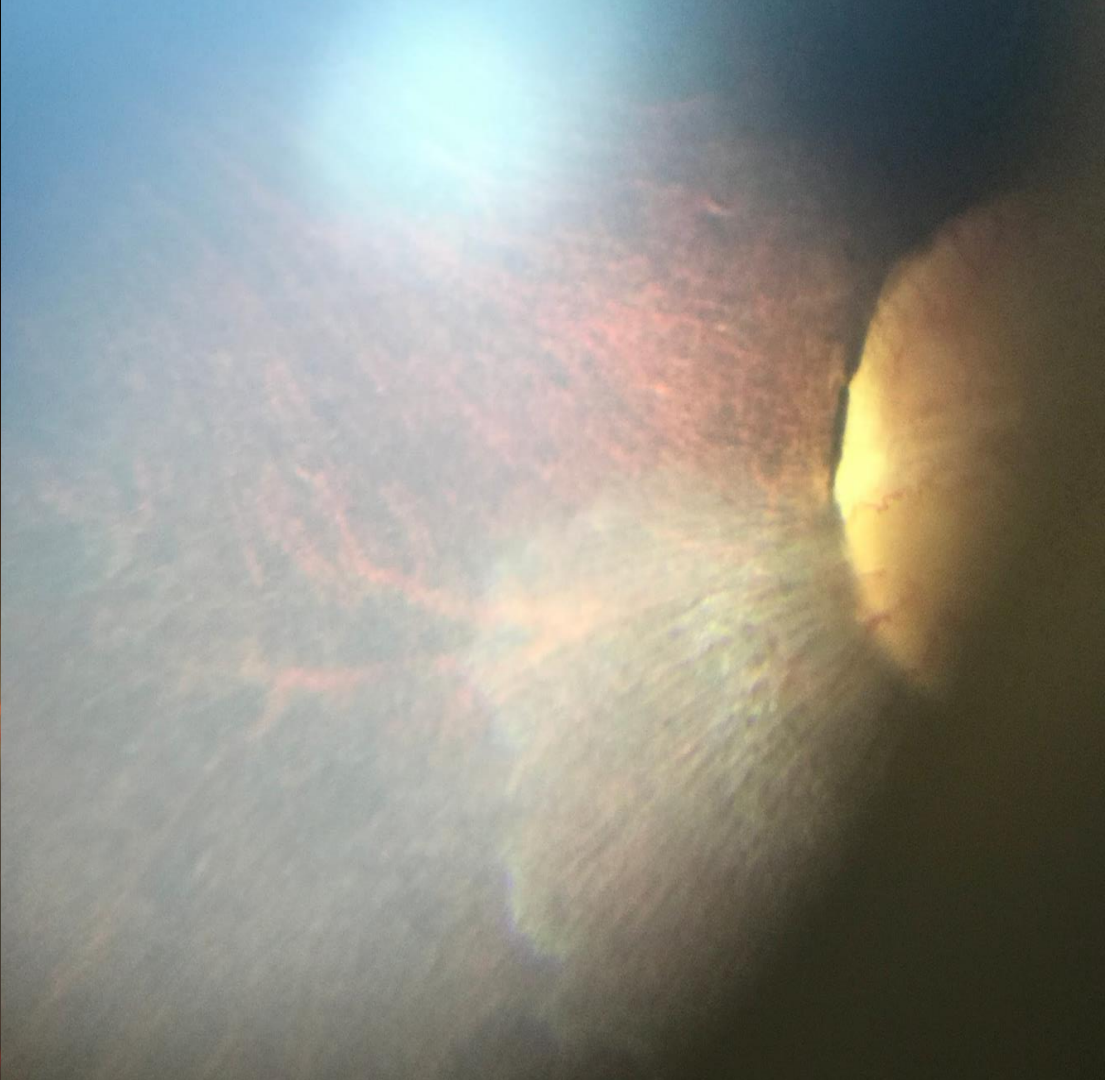
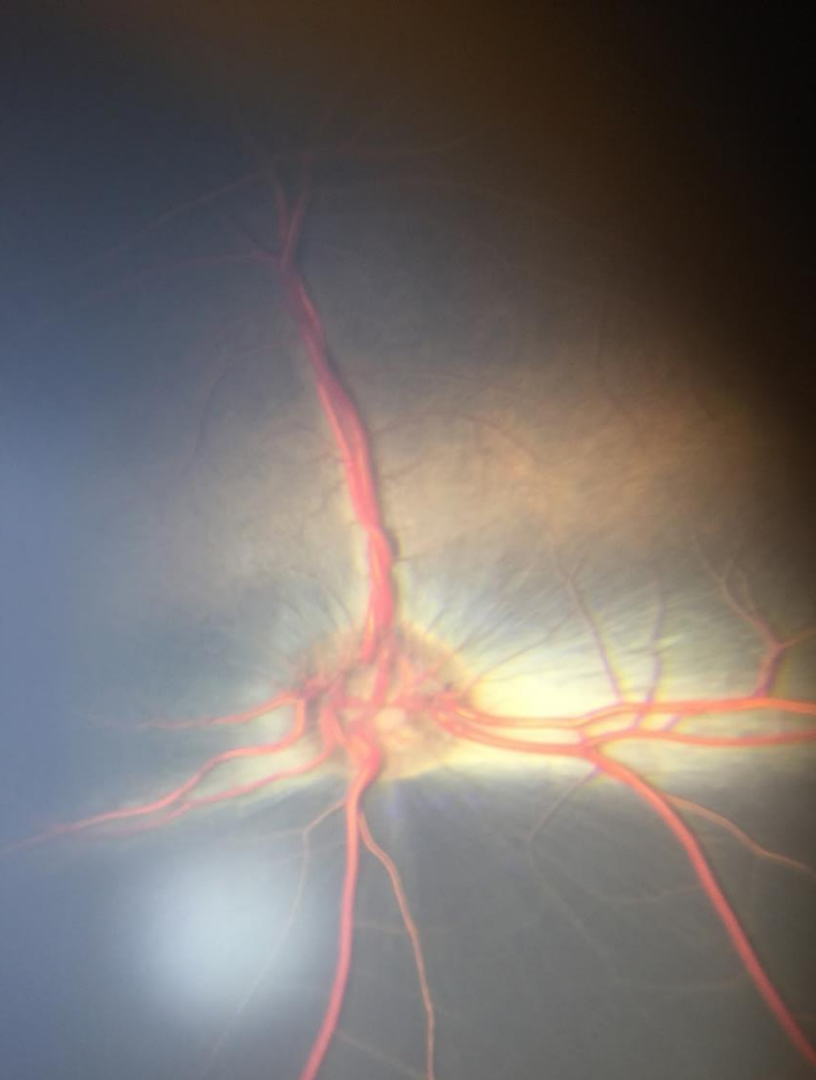
Optic nerve head


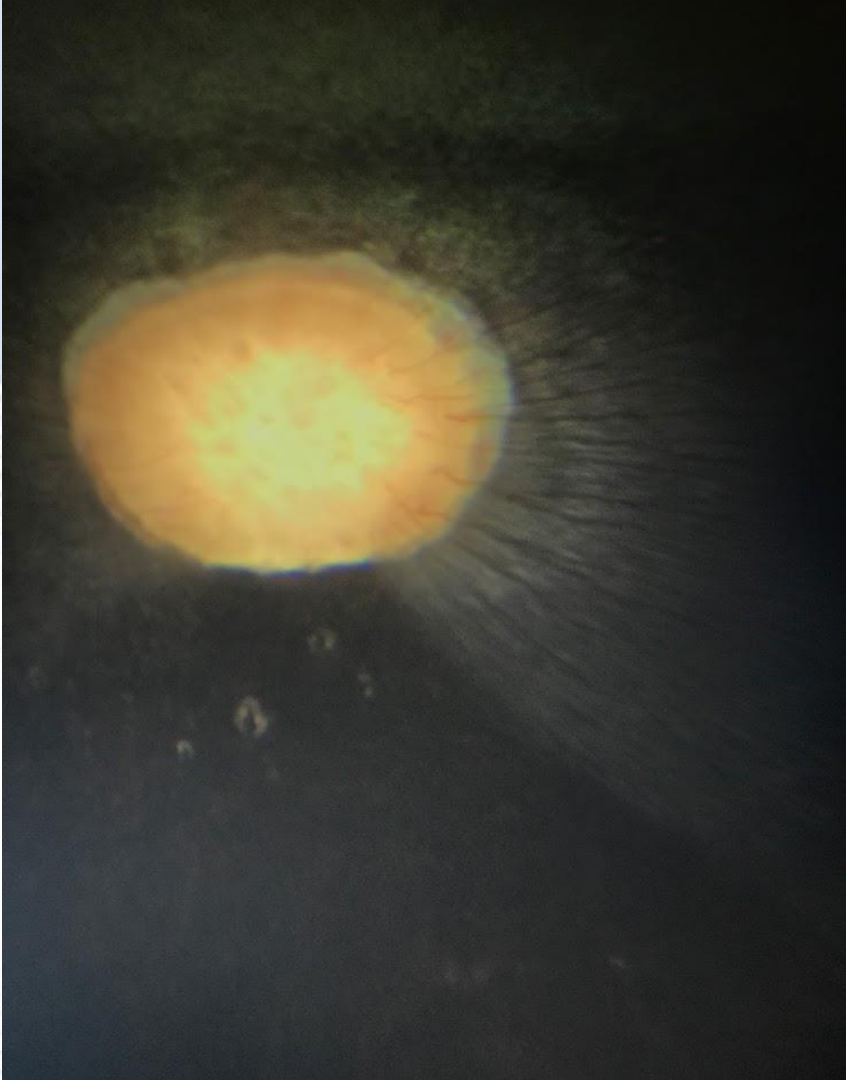

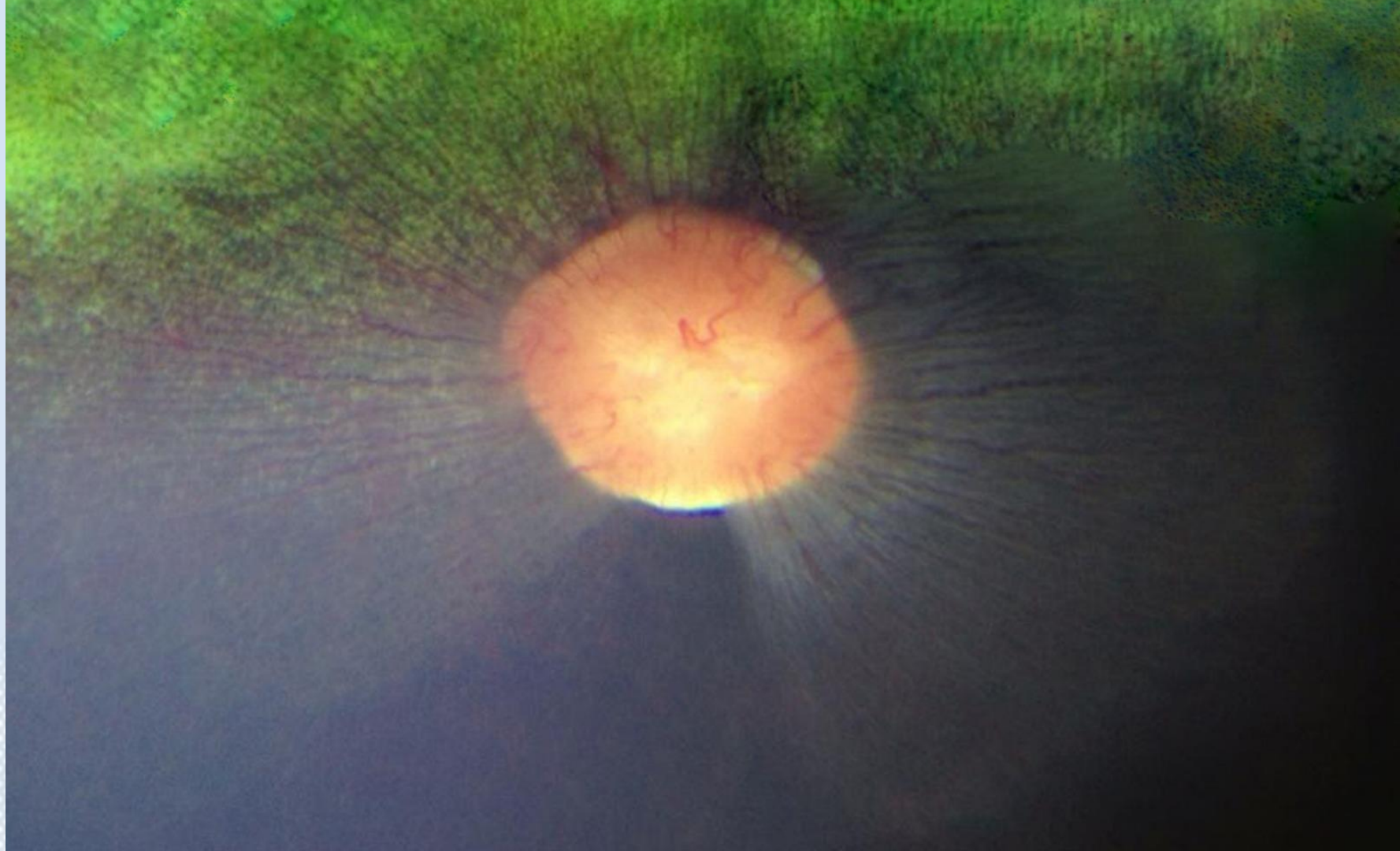




Nerve fibre layer

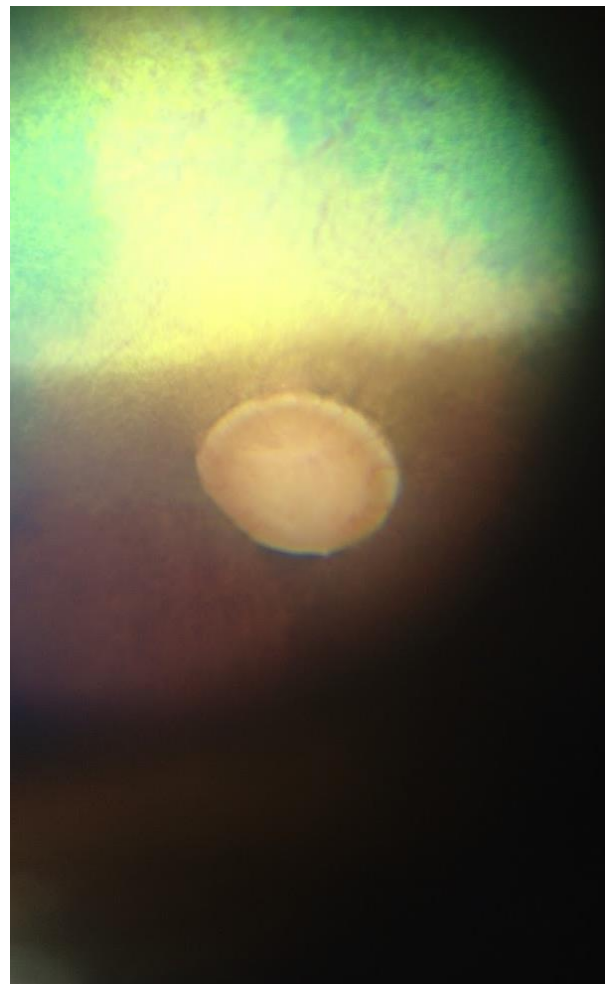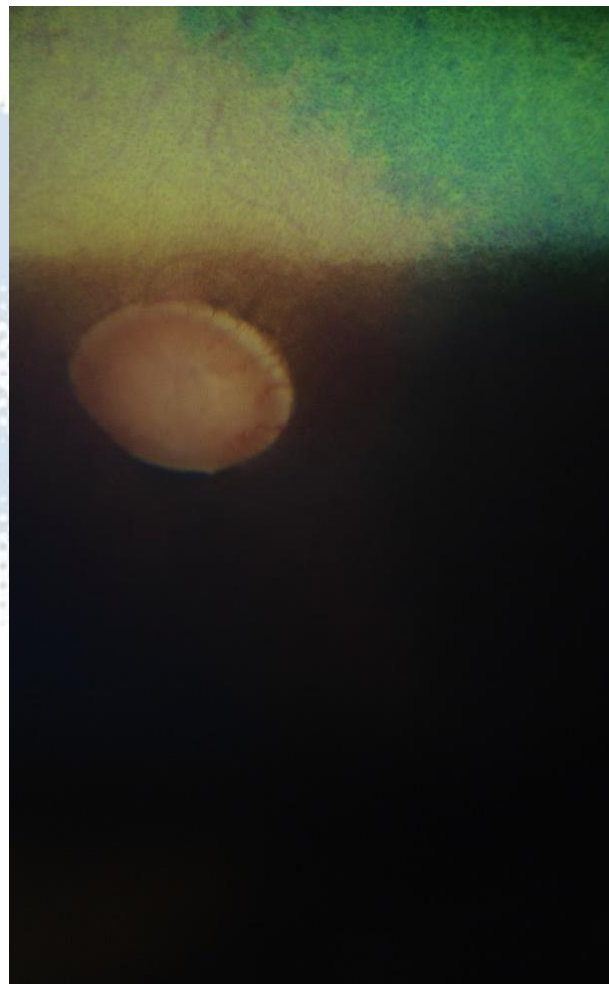

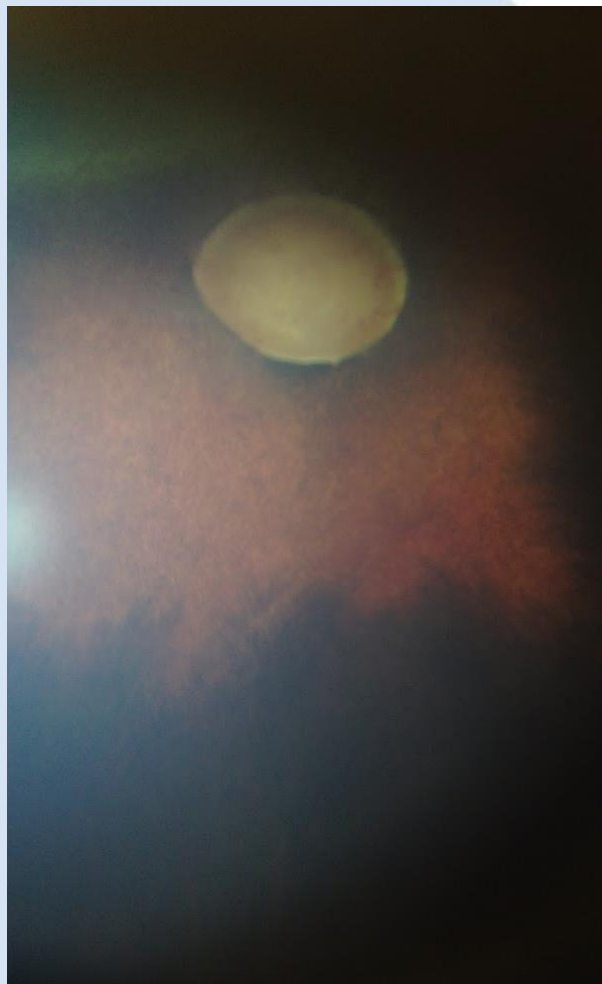


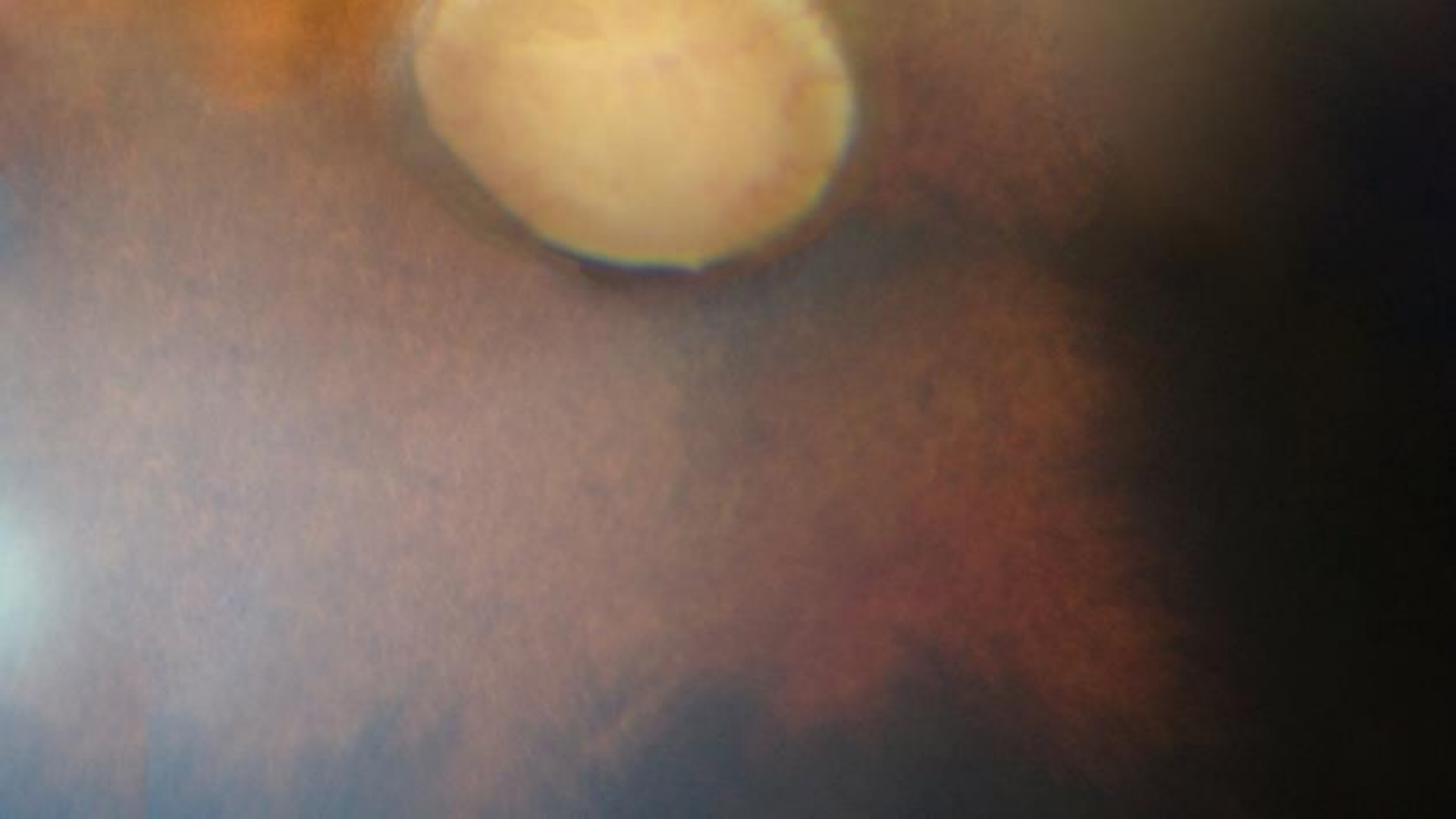


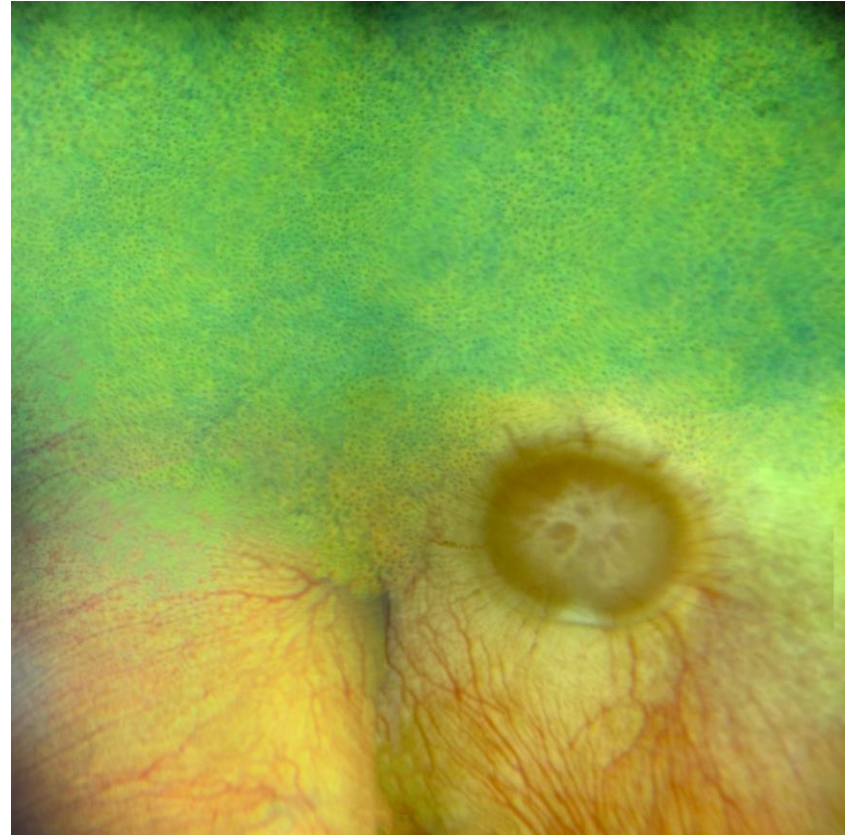

Non tapetal fundus



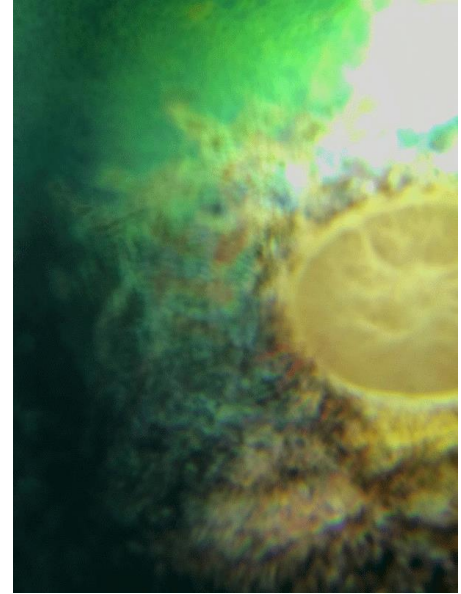
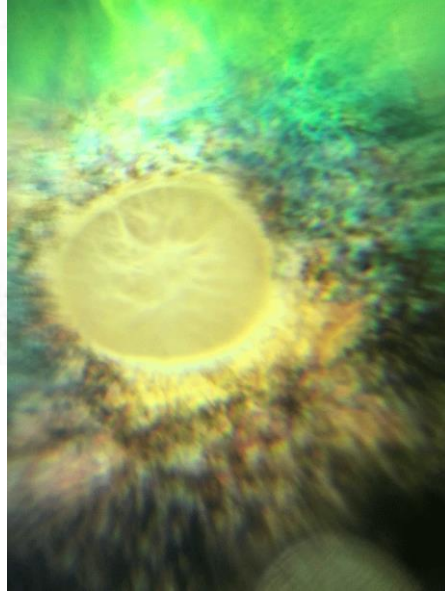
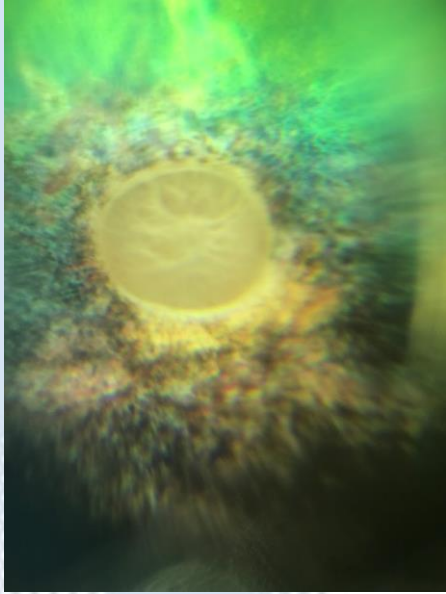

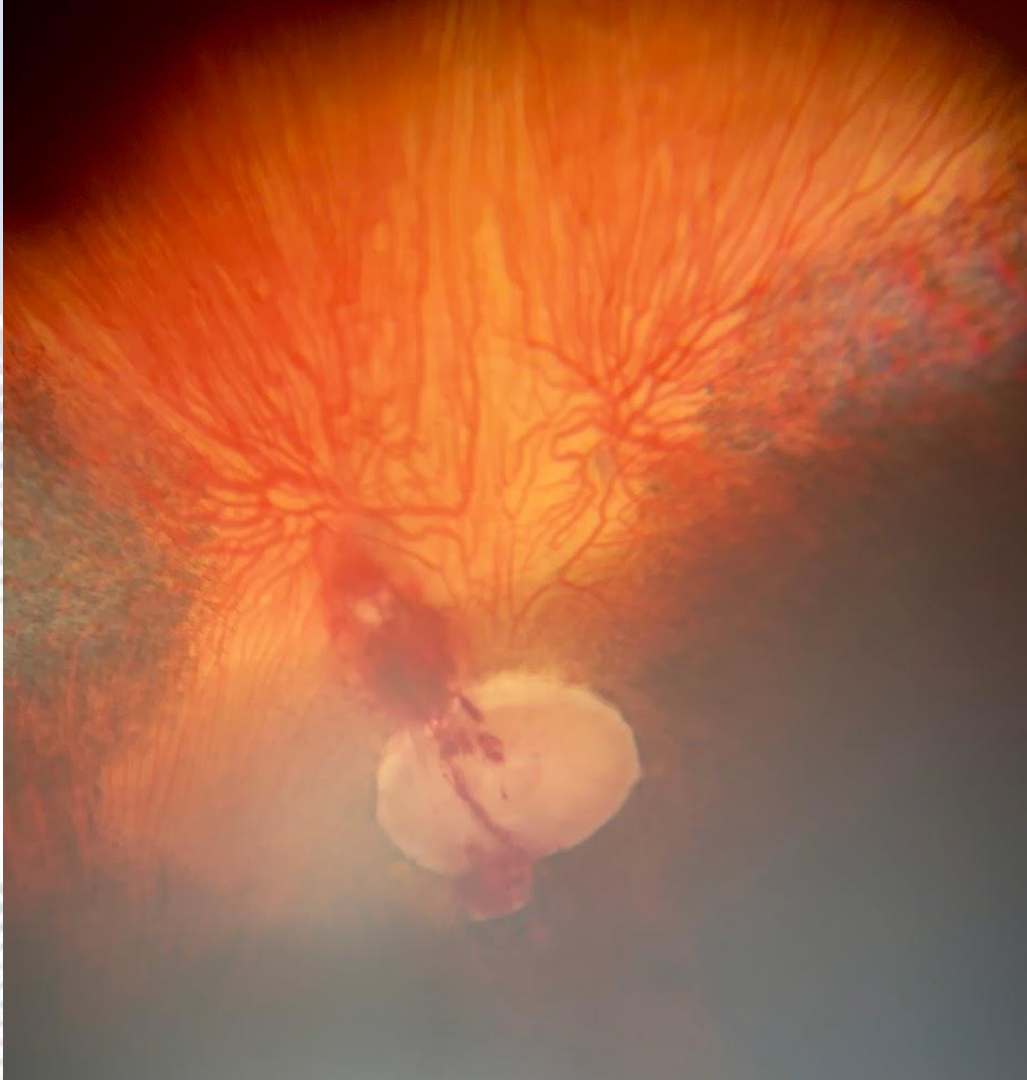





Tapetal fundus

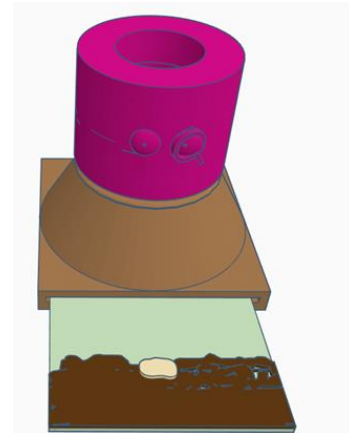
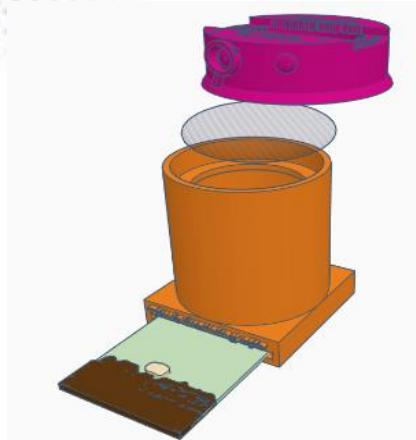
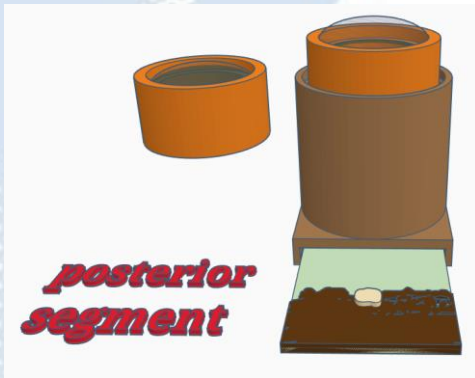
Tapetal hyperreflectivity



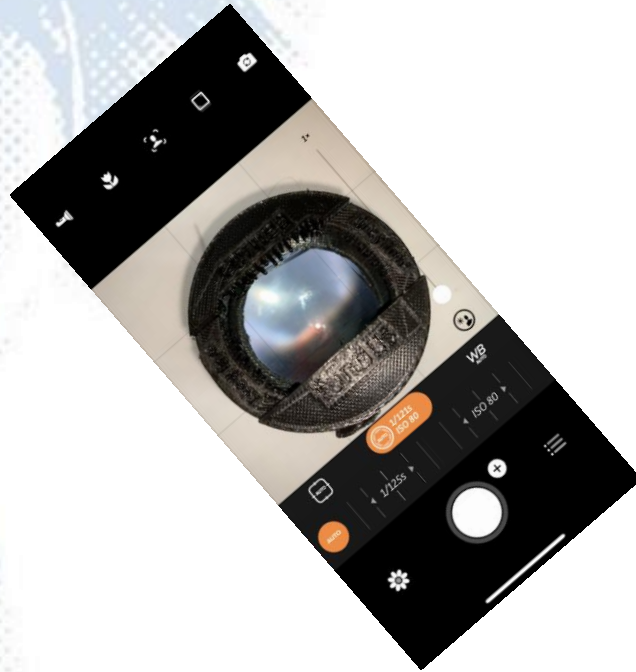



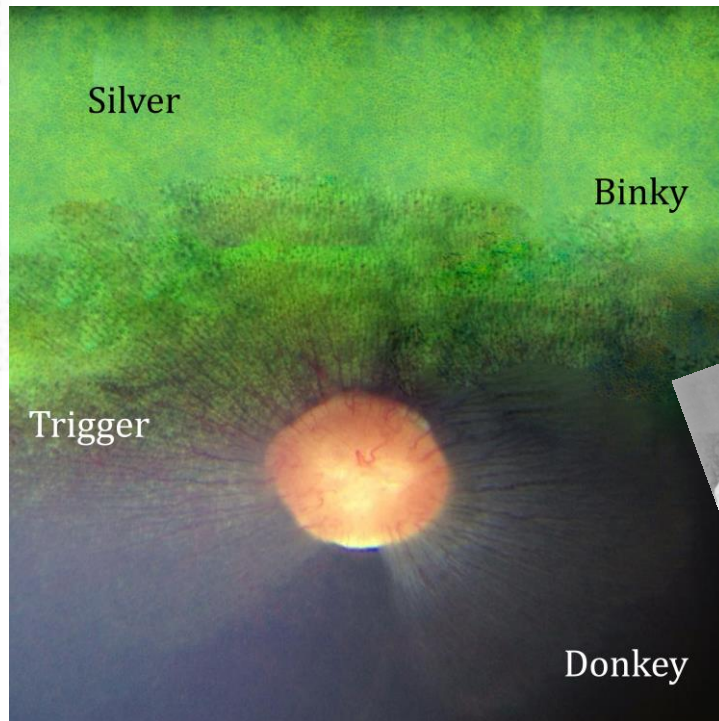
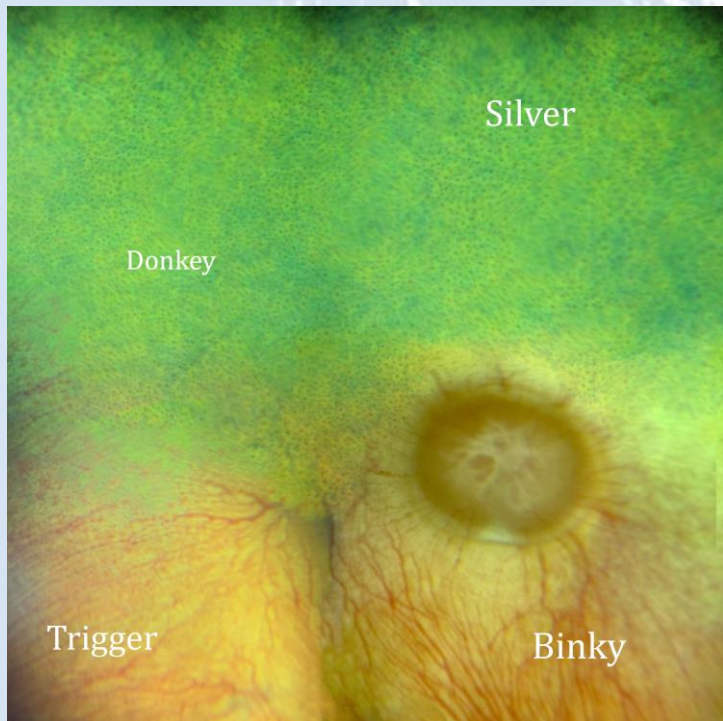
Practical session 4: posterior segment



Task 1: Use Distant direct to identify anterior vitreal or peripheral retinal abnormalities using eye model



Task 2: Use close direct phoneoscopy to directly image the fundus



Thanks for listening

